

Total Spondylectomy of C2: a New Surgical Technique

Totální spondylektomie C2: nová operační technika

J. ŠTULÍK¹, J. KOZÁK², P. ŠEBESTA¹, T. VYSKOČIL¹, J. KRYL¹, M. PELICHOVSKÁ³

¹ Department of Spinal Surgery, University Hospital Motol, Prague

² Department of Stomatology, 2nd Faculty of Medicine and University Hospital Motol, Prague

³ Department of Anaesthesia and Resuscitation, 2nd Faculty of Medicine and University Hospital Motol, Prague

ABSTRACT

According to the available sources, no case of total spondylectomy of C2 with preservation of roots, preservation of vertebral arteries and a short fixation without occipitocervical fusion has been so far described in the literature.

We decided to perform a radical surgery in a man, now 27 y. o., with solitary metastasis of thyroid adenocarcinoma. In the first step, we applied the posterior surgical approach. The patient was placed prone on a standard operating table with a support of head fixed by adhesive plaster, with the upper cervical spine slightly bent forward. We made a mid-line incision, extending from the external occipital protuberance to the C7 spinous process, controlled bleeding and exposed the C0-C4 section. Subsequently, the entire posterior epistropheus was resected, including most of the pedicles and the entire articular processes for C2-C3 articulation. Both the C2 roots were preserved, however, we had to control quite a profuse bleeding from the venous plexus around the left root. During dissection, the dural sac was damaged in the region of the attachment of the left root, which was treated by suture and covered with Tissucol fibrin sealant. Screws 4.0 mm thick, were inserted into the lateral masses of the atlas after Harms and 4.0mm screws into the C3 and C4 articular processes. On both sides, the screws were connected with 3.2 mm rods, and a transverse stabilizer was then applied to fix the two sides together. Cancellous bone grafts were harvested from the iliac crest and a massive posterolateral and posterior fusion of C1-C4 was performed. The second operation was performed after 21 days. Transoral transmandible approach without tongue splitting was applied. The patient was placed supine on a standard operating table with a support of neck, the head was fixed by adhesive plaster and slightly bent back, and tracheostomy was inserted. An arched incision through the middle of the red lip was made, extending 2 cm straight caudally and arching across the chin and neck, in the midline. On the caudal end we made a transverse inverted T incision. Subsequently, we exposed and osteotomised the mandible using the midline Z-type incision. In order to identify the space between the anterior arch of C1 and the C4 vertebral body, the Synframe retractor was inserted with one blade opening the mouth by pressure on the upper teeth and two blades pressing the tongue caudally. Then an inverted U incision through the mucosa of pharynx was made to identify paravertebral muscles. Caspar retractor was used to separate the muscles and expose C1-C3 laterally, including transversal processes with vertebral arteries. No pathological changes were manifested on the skeleton. First we removed the middle portion of the C2 vertebral body where we did not find any tumour, only sclerotic remodelling. Subsequently, we reamed the lower middle portion of the anterior arch of C1, extracted the dens and cut off the alar ligaments and the apical ligament of dens. The entire dens was then removed. Then we continued on the right side, in the intact part and extracted part of C2 in the region of the atlantoaxial joint, including the rest of the pedicle, and the anterior portion of the transversal process up to the vertebral artery. The posterior part of the transversal process was carefully rotated around the artery and also removed. All parts were extremely hard, sclerotic. The same procedure was followed on the left side where we found a 7x10 mm gelatinous greyish tumour in the lateral part of C2 below the atlantoaxial joint. Other parts were again sclerotic. Liquorrhea appeared again from dissection around the C2 root on the left side, the source of which we could not clearly identify. We filled the site of the probable hole with Tissucol fibrin sealant. Between the notch in the lower part of the anterior arch of C1 and the upper end plate of the C3 vertebral body we seated a shaped SynMesh cage with sharp edges providing a very good fixation. No additional fixation was needed. Again we harvested cancellous bone grafts from the iliac crest and placed them on the sides of the cage and at the front between the anterior arch of the atlas and the C3 vertebral body. Subsequently, the muscles were approximated and the mucous tissue of the pharynx repaired. The mandible was fixed by two Miniplate System plates and supported by a dental plate.

Total spondylectomy of C2 with preservation of vertebral arteries and roots stabilized only by a short fixation is an extreme surgical procedure suitable only for exceptional cases of young patients with a good bone quality. With regard to potential complications it is of vital importance to consider carefully such operation and consult the proposed therapy with the patient.

Key words: total spondylectomy, axis, epistropheus, C2, cervical spine.

INTRODUCTION

Progress in the surgical technique and an intensive development of instrumentation for stabilization of the spine allow applying ever more aggressive surgical techniques. Complete resection of the entire mobile segment offers new possibilities in the treatment of primary spinal malignancy. Total en bloc spondylectomy for primary tumor of the thoracolumbar spine has been described in the literature many times (1, 17, 26). However, these techniques cannot be used in the region of the cervical spine as it is necessary to preserve cervical nerve roots and vertebral arteries, the resection or ligation of which may cause a severe injury to the patient (5). Cohen et al. (5) from the Anderson Cancer Center described total intralesional resection of C6 with preservation of the roots and vertebral arteries for primary osteosarcoma, Rhines et al. (20) from the same Centre reported en bloc spondylectomy of C2-C4 for chordoma, combined with ligation of one vertebral artery and dissection of roots on one side. According to the available sources, no case of total spondylectomy of C2 with preservation of roots, preservation of vertebral arteries and a short fixation without occipitocervical fusion has been so far described in the literature.

CASE STUDIES AND DESCRIPTION OF SURGICAL TECHNIQUE

Case history

A man, now 27 years old, underwent in 2001 thyroidectomy for adenocarcinoma of the thyroid. In 2005 he was reoperated on for a local recurrence of the tumour. Both surgeries were performed at the ORL Department of the University Hospital in Motol, Prague. Since 2001, the patient has been treated at the Department of Endocrinology of the University Hospital in Motol, Prague and at the Department of Nuclear Medicine of the University Hospital in Motol, Prague. In September 2006, the patient complained of pain in the neck. The attending physician indicated a whole-body PET CT scan that revealed a solitary pathological process in the epistropheus. The patient was referred to the Department of Spinal surgery of the University Hospital Motol for additional examination and determination of the subsequent therapy.

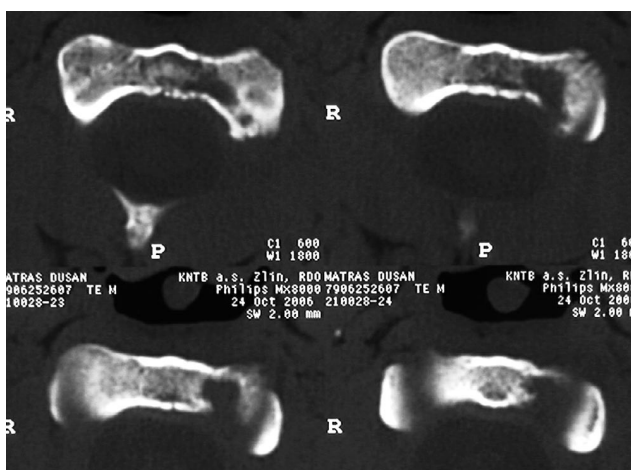
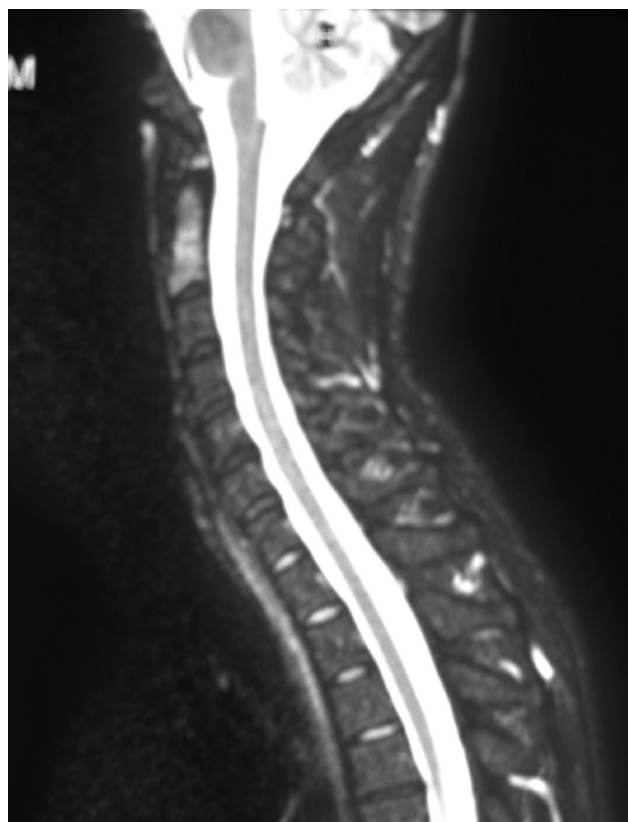
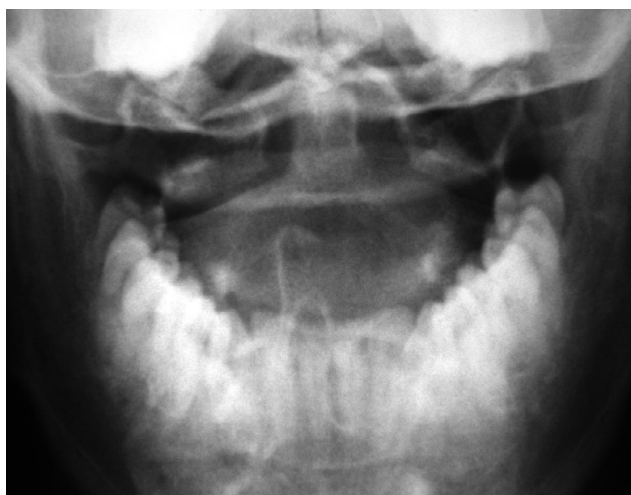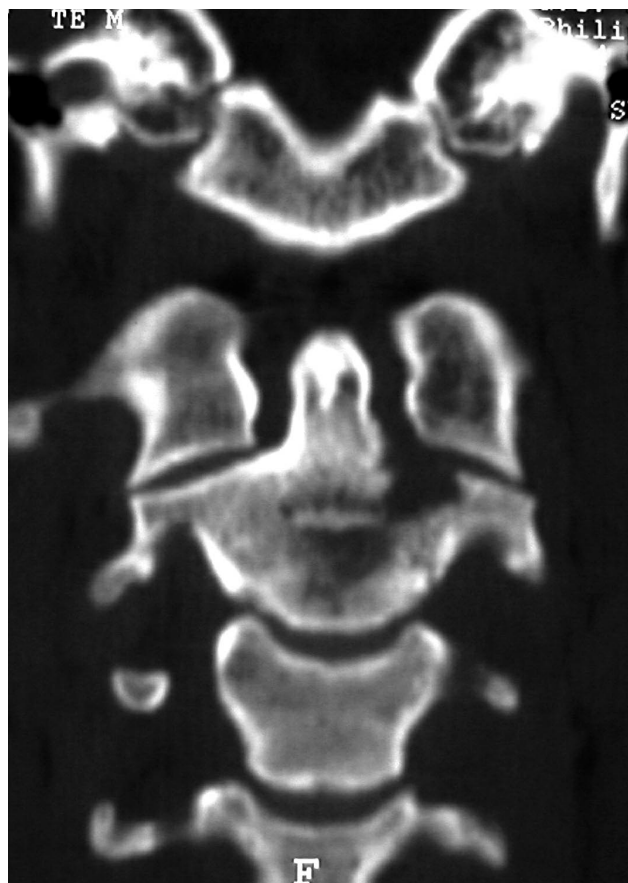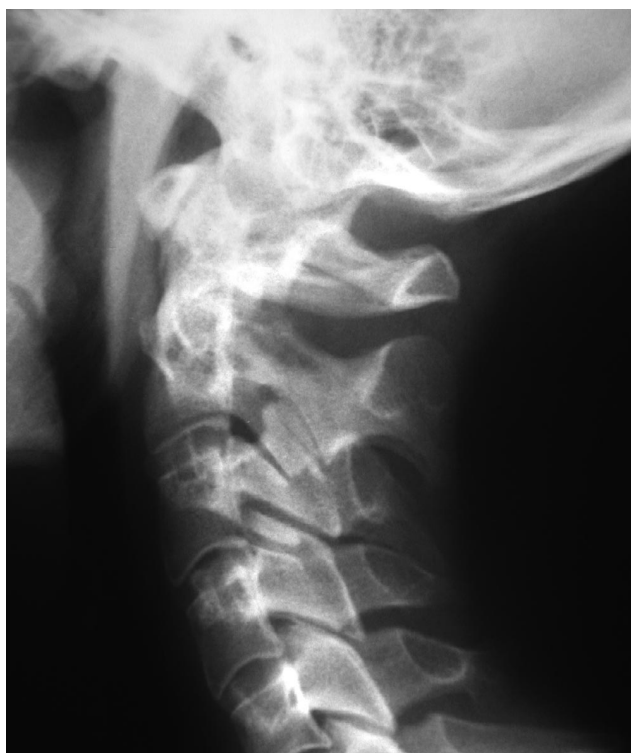Diagnosis

At our Department, we completed the diagnostic mosaic by a standard x-ray examination in ap, transoral and lateral projections, thin-section CT scan of C1-C3 with sagittal and frontal reconstruction, MRI examination of the cervicocranial junction and angiography of the same location. The standard lateral and ap radiographs did not show any pathology, while the transoral radiograph disclosed a slight radiolucency of 5x7 mm in the lateral part of the C2 body below the left

atlantoaxial joint. The same finding was confirmed by CT scan and MRI which, in addition showed a mono-compartmental localization. The tumour did not exceed the edges of the epistropheus and there was no response of the surrounding soft tissues (Fig. 1a-e). Other parts of C2 (dens, body, articular processes, the whole posterior part on the right) manifested sclerotic reactive remodelling of the bone tissue. Angiographic examination did not reveal any pathological vascularization.

Surgical technique

After a careful study of all examinations and consultation with the patient we decided to perform a radical surgery. In the first step, we applied the posterior surgical approach. The patient was placed prone on a standard operating table with a support of head fixed by adhesive plaster, with the upper cervical spine slightly bent forward. We made a mid-line incision, extending from the external occipital protuberance to the C7 spinous process, controlled bleeding and exposed the C0-C4 section. Subsequently, the entire posterior epistropheus was resected, including most of the pedicles and the entire articular processes for C2-C3 articulation. Both the C2 roots were preserved, however, we had to control quite a profuse bleeding from the venous plexus around the left root. During dissection, the dural sac was damaged in the region of the attachment of the left root, which was treated by suture and covered with Tissucol fibrin sealant. Screws 4.0 mm thick, were inserted into the lateral masses of the atlas after Harms (13, 25) and 4.0mm screws into the C3 and C4 articular processes. On both sides, the screws were connected with 3.2mm rods, and a transverse stabilizer was then applied to fix the two sides together. For stabilization we used Vertex instrumentation (Medtronic, Memphis, Tennessee, US). Cancellous bone grafts were harvested from the iliac crest and a massive posterolateral and posterior fusion of C1-C4 was performed (Fig. 2). In order to control profuse bleeding, we inserted Redon drain, but with regard to liquorrhea, only without suction. The wound was closed in layers. The operative time was 3 hours and the blood loss 1200 ml. After the surgery, the patient was transferred to the Department of Anaesthesiology and Resuscitation for stabilization of his general condition. On the second postoperative day, he was transferred back to our Department. Redon drain was removed on 4th postoperative day. After the first surgery, no complications were encountered until 17th day when we detected soft resistance posteriorly in the region of the surgical wound, with fluctuation. Suspected liquorrhea was confirmed by puncture. After agreement with the patient, revision of the wound and repair of the dura mater was scheduled simultaneously with the anterior surgery. The second operation was performed after 21 days. Transoral transmandible approach without tongue splitting was applied. The patient was placed supine on a standard operating table with a support of neck, the head was fixed by adhesive plas-



a | d
b | e
c | e

Fig. 1. Patient, a man 27-years old, with metastasis of adenocarcinoma of thyroid to the epistropheus: a) preoperative lateral radiograph, b) preoperative transoral projection, c) preoperative transversal CT scans, d) preoperative CT frontal reconstruction, e) preoperative MRI.

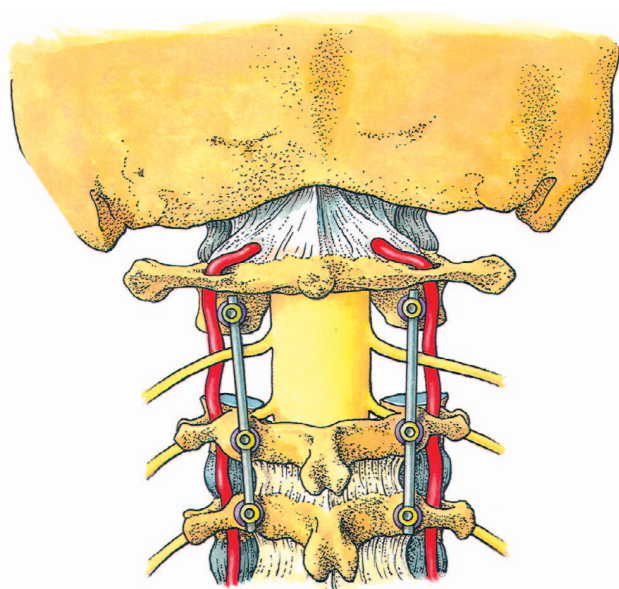


Fig. 2. Resection of the posterior epistropheus and stabilization of C1-C3-C4 by Vertex fixator (Medtronic, Memphis, Tennessee, US) in the first step, an artist's depiction.

ter and slightly bent back, and tracheostomy was inserted. An arched incision through the middle of the red lip was made, extending 2 cm straight caudally and arching across the chin and neck, in the midline. On the caudal end we made a transverse inverted T incision (Fig. 3). Subsequently, we exposed and osteotomised the mandible using the midline Z-type incision. In order to identify the space between the anterior arch of C1 and the C4 vertebral body, the Synframe retractor (Synthes, Oberdorf, Switzerland) was inserted with one blade opening the mouth by pressure on the upper teeth and two blades pressing the tongue caudally. Then an inverted U incision through the mucosa of pharynx was made to identify paravertebral muscles. Caspar retractor was used to separate the muscles and expose C1-C3 laterally, including transversal processes with vertebral arteries (Fig. 4a-f). No pathological changes were manifested on the skeleton. First we removed the middle portion of the C2 vertebral body where we did not find any tumour, only sclerotic remodelling. Subsequently, we reamed the lower middle portion of the anterior arch of C1, extracted the dens and cut off the alar ligaments and the apical ligament of dens. The entire dens was then removed. Then we continued on the right side, in the intact part and extracted part of C2 in the region of the atlantoaxial joint, including the rest of the pedicle, and the anterior portion of the transversal process up to the vertebral artery. The posterior part of the transversal process was carefully rotated around the artery and also removed. All parts were extremely hard, sclerotic. The same procedure was followed on the left side where we found a 7x10 mm gelatinous greyish tumour in the lateral part of C2 below the atlantoaxial joint. Other parts were again sclerotic. Liquorrhea appeared again from dissection around the C2 root on the left side, the sour-

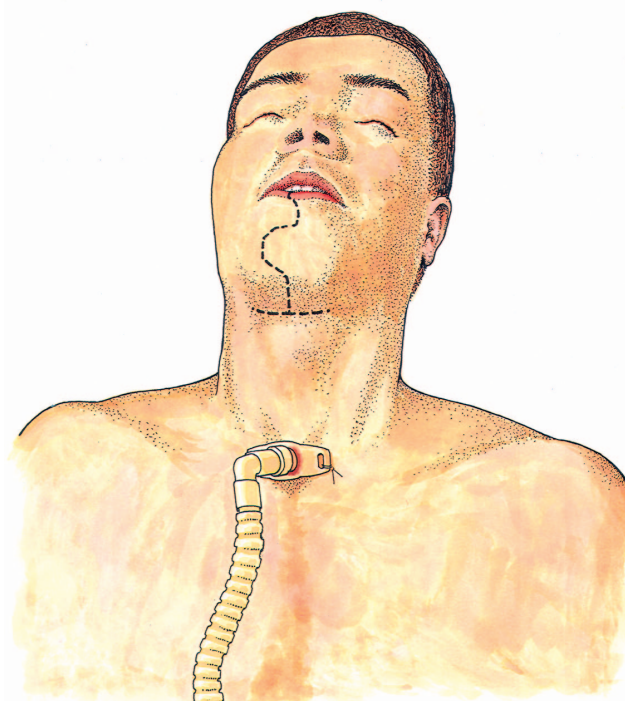
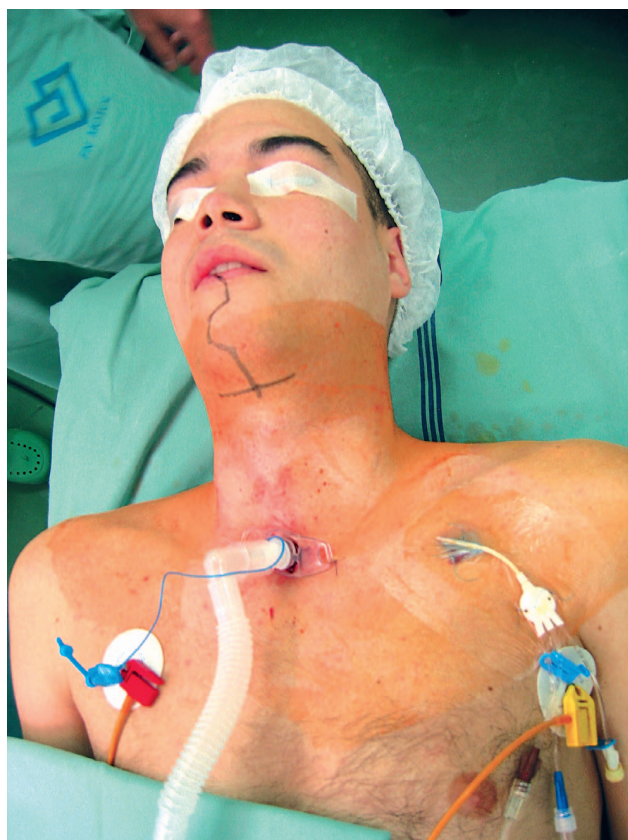

Fig. 3. Position of the patient on the operating table in the second step, marking the incision: a) peroperative photo, b) an artist's depiction.

ce of which we could not clearly identify. We filled the site of the probable hole with Tissucol fibrin sealant. Between the notch in the lower part of the anterior arch of C1 and the upper end plate of the C3 vertebral body we seated a shaped SynMesh cage (Synthes, Oberdorf,

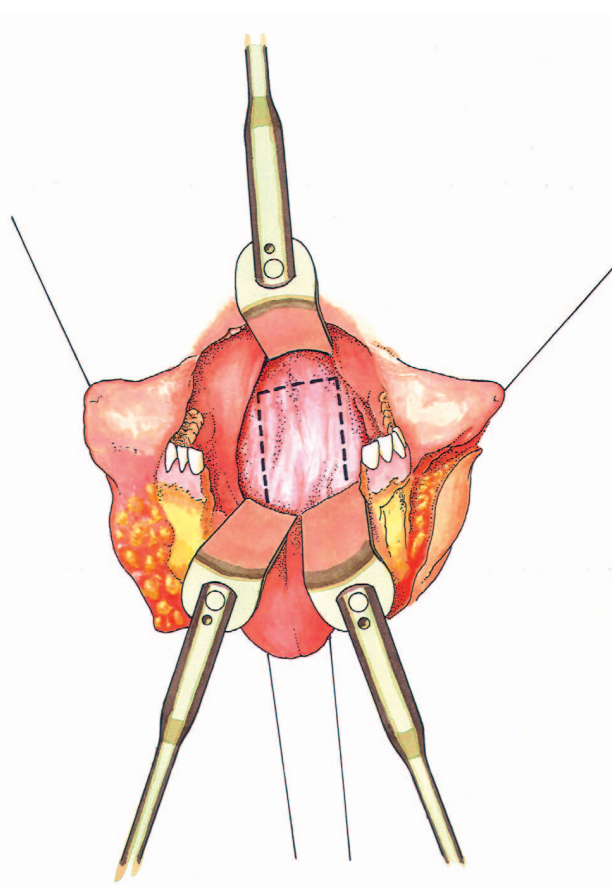
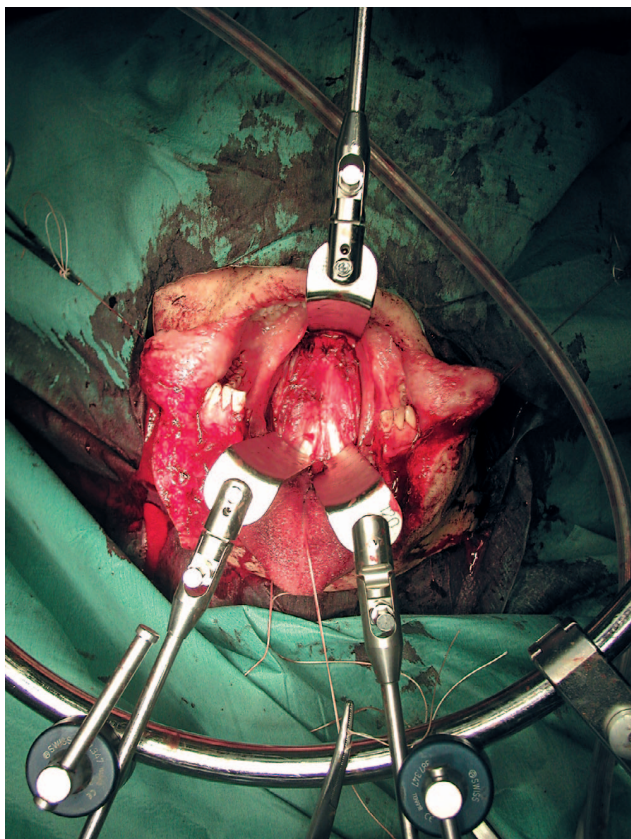
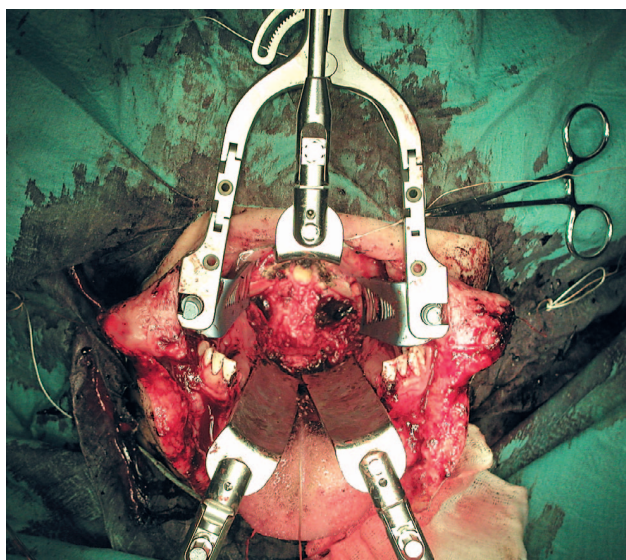
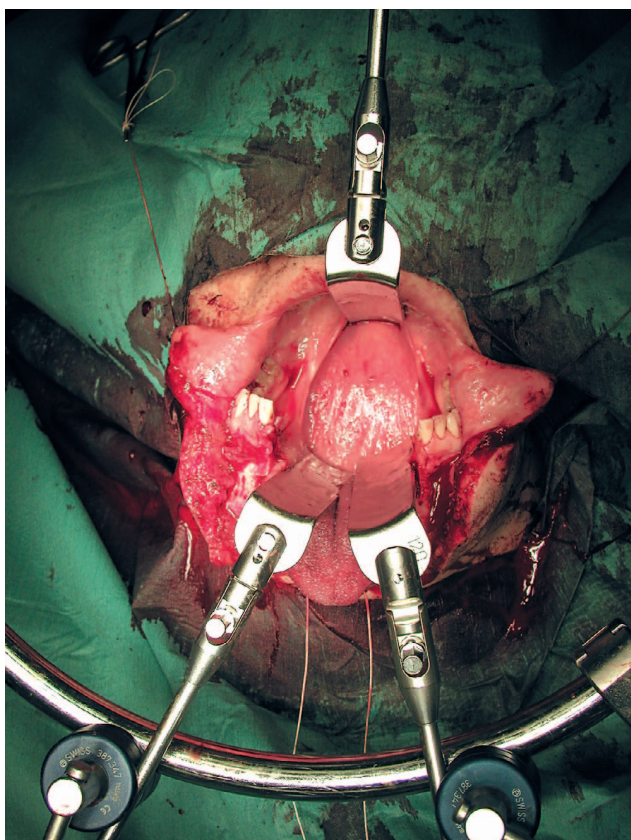


Fig. 4. Transoral, transmandibular approach to the epistropheus, incision in the pharynx, exposure: a, b, c) peroperative photo, d, e, f) an artist's depiction.

a|c
b|d

Fig. 4e + 4f ►

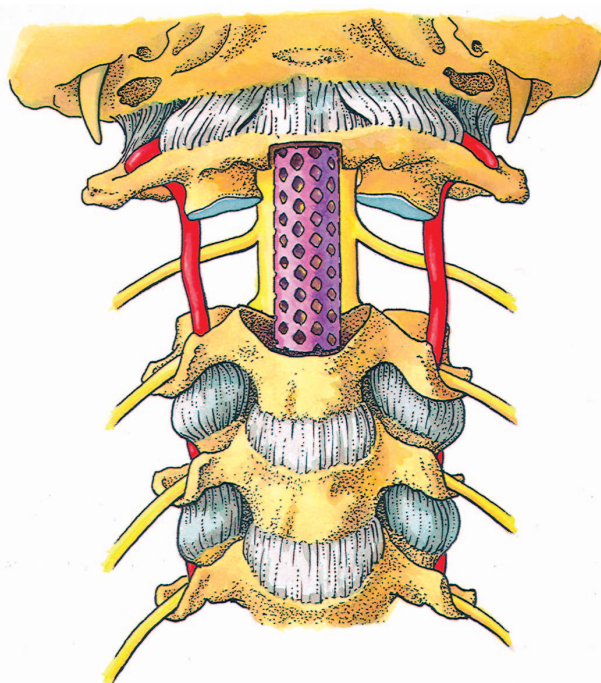
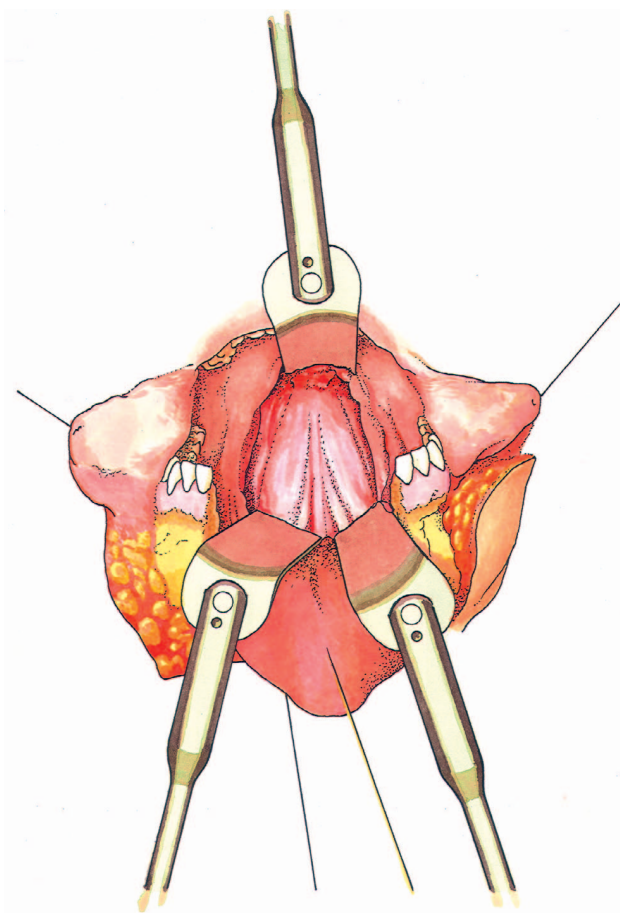
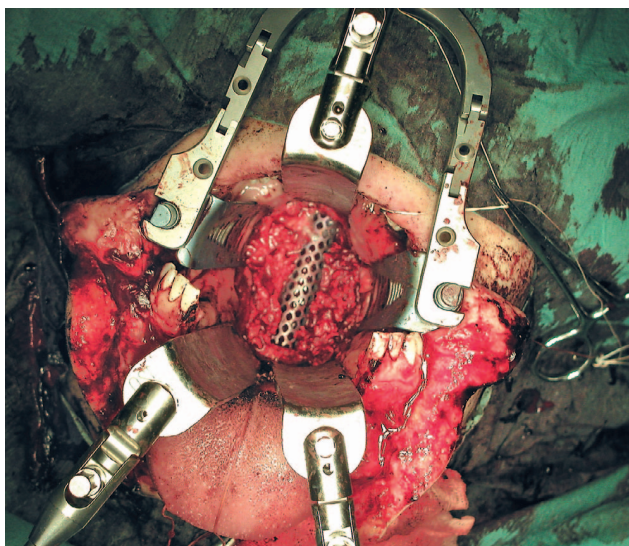


Fig. 4f ▲

Fig. 4e ◀



a|b

Switzerland) with sharp edges providing a very good fixation. No additional fixation was needed (Fig. 5a, b). Again we harvested cancellous bone grafts from the iliac crest and placed them on the sides of the cage and at the front between the anterior arch of the atlas and the C3 vertebral body. Subsequently, the muscles were approximated and the mucous tissue of the pharynx repaired. The mandible was fixed by two Miniplate System plates (Lorenz, Biomet, Jascjsonville, Florida, US)

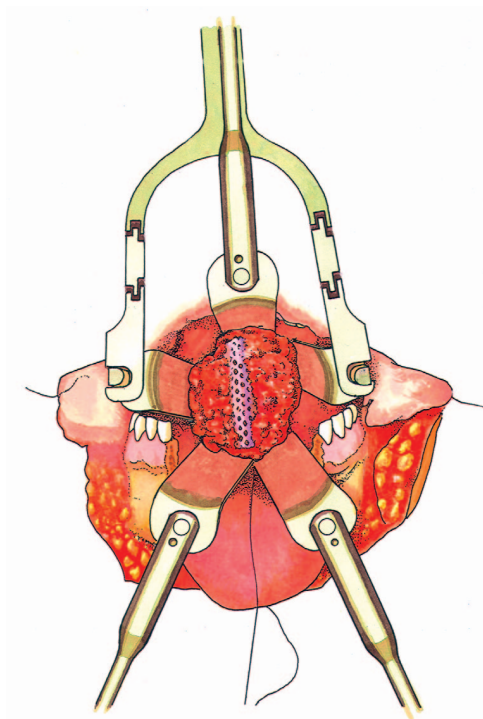


Fig. 5. Replacement of the epistropheus by the SynMesh titan cage (Synthes, Oberdorf, Switzerland) and application of cancellous bone grafts: a) peroperative photo, b) an artist's depiction.

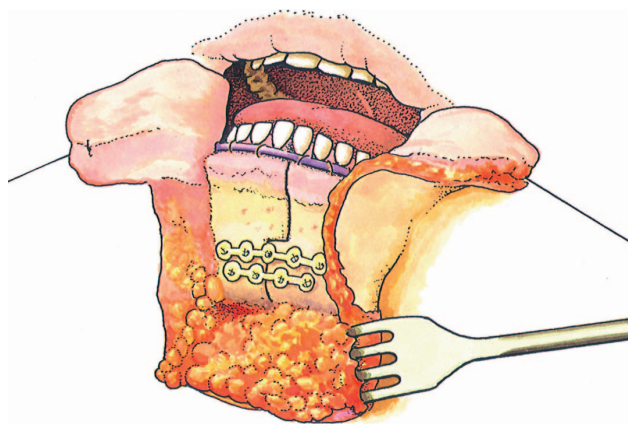
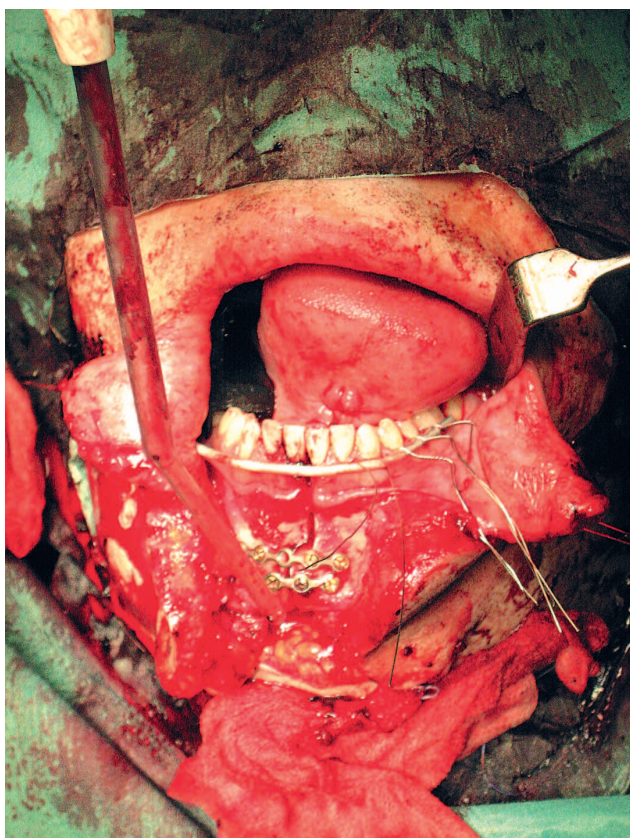
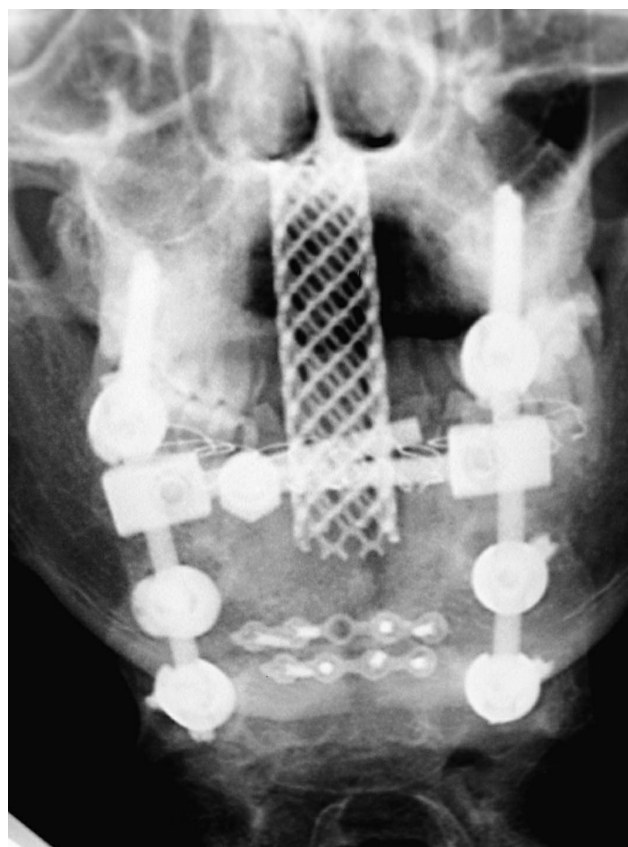
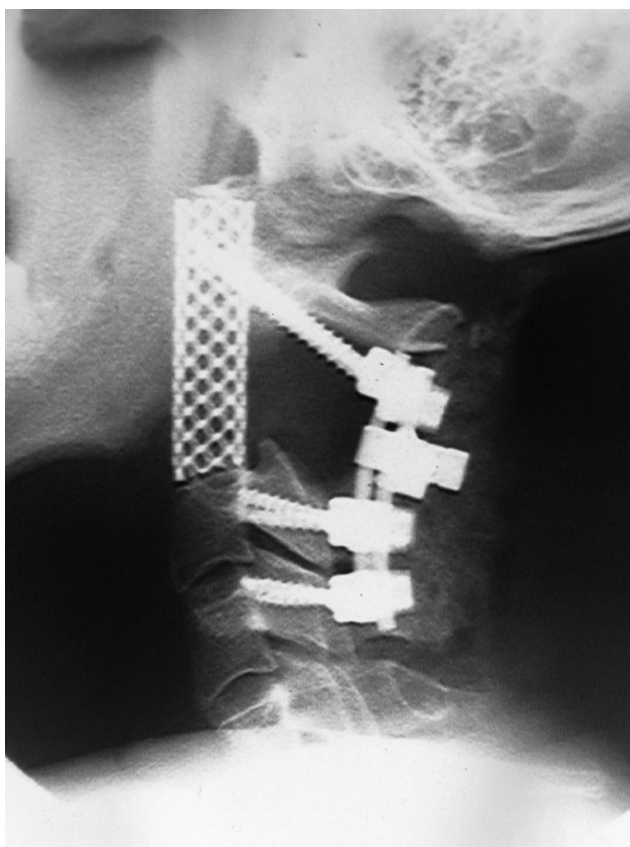


Fig. 6. Internal fixation of the mandibula by the Miniplate System (Lorenz, Biomet, Jacksonville, US) and wound closure: a) peroperative photo, b) an artist's depiction.

and supported by a dental plate (Fig. 6a, b). Soft tissues were sutured in layers and a thin Redon drain placed subcutaneously. The surgery took 8 hours and the blood loss was 300 ml (Fig. 7a, b). Under one anaesthesia we revised the posterior approach, drained away liquor and again filled the point of perforation with the fibrin glue. The wound was sutured in layers and a subdural

a|b



a b

Fig. 7. Condition after total resection of C2: a) lateral radiograph, b) transoral radiograph.

catheter was inserted in the lumbar region. The patient was provided with a rigid Philadelphia collar and transferred to the Department of Anaesthesiology and Resuscitation for stabilization of his general condition.

Postoperative care

Starting from the second postoperative day the patient was conscious, stabilized, without any significant pain and without functional impairment. However, he had a bitter-sweet taste in his mouth and during follow-up we found a massive liquorrhea in the mouth and a recurred resistance in the posterior region of the surgical wound. Despite draining off up to 400 ml of liquor daily from the lumbar catheter, liquorrhea was persisting. On 5th postoperative day we decided to perform bilateral revision. First, we revised the posterior approach, removed the transverse stabilizer and grafts, located the defect in the dura mater in the region of the attachment of the C2 root on the left side. Subsequently we covered the defect with Surgicell, used the fibrin glue, applied the Redon drain without suction and sutured the wound in layers. Then we turned the patient and revised the partially disintegrated wound in the mucosa of pharynx, repaired the defect, drained off the liquor transmucosally from the cage with a syringe and applied inside the fibrin glue. Lumbar drain was left in place draining off about 350 ml of liquor daily. On 6th day after the anterior surgery we applied percutaneous endoscopic gastrostomy (PEG). In the following period liquorrhea did not recur in the mouth or in the posterior approach and the patient was in a good condition transferred to a standard ward. Lumbar drainage was gradually reduced and on 18th postoperative day the catheter was extracted. Redon drain from the posterior approach was extracted on 9th day after revision. The patient was gradually recovering and tolerated soft diet. SOMI brace was applied and the patient was gradually allowed to stand up. After 50 days of hospitalization he was discharged in a good condition, without any signs of liquorrhea, without headache and without functional impairment. Control radiographs show a good position of the cervical spine and the instrumentation, the caudal end of the cage is displaced by 1 mm anteriorly. During the last follow-up, 3 months after the primary surgery, there were no signs of recurrence and the radiograph showed a posterior C1-C4 and anterior C1-C3 bone fusion.

DISCUSSION

Three major issues are discussed in terms of extensive surgical procedures in the region of the upper cervical spine and the craniocervical junction, namely indication for surgery, the surgical approach and the actual technique of removal of the pathological lesion.

Extensive resection procedures are indicated almost exclusively for tumour, most often for the primary one.

Primary tumours located in the region of the upper cervical spine and the craniocervical junction are quite rare. They may be benign or malignant, most frequent is the chordoma. Chordoma accounts for 1-4 % of all primary bone tumours (3, 4). In the sacrococcygeal region it may be found in 45 % of cases, on the skull base in 40 % and the remaining 15 % relate to the spine, cervical in particular. Chordoma develops from the persistent portions of the primitive notochord that is an embryological precursor of the axial skeleton (3, 4, 24). Most often it is soft and gelatinous, but it may also be fibrous and rigid which complicates its surgical removal (8). Chordoma of the cervical vertebra typically affects the vertebral body and expands into perivertebral soft tissues and the epidural space (23). Chordoma grows slowly and prior to the development of symptoms leading to the diagnosis it may become quite sizeable. Most frequently it is diagnosed in the age group of 50-69 years, with men affected twice more often (3, 4, 24). If we exclude chordoma, then most publications deal with individual case studies or very small groups of patients. The only exception are George et al. (11) who report in a group of 77 patients with a primary tumour 36 chordomas, 8 osteoid osteomas, 5 osteochondromas, 4 plasmocytomas, 3 histiocytoses, 3 cases of fibrous dysplasia, 3 aneurysmatic bone cysts, 3 osteoblastomas, one Ewing sarcoma and one giant-cell tumour of bone. The group was followed up for 21 years and during the same period the authors treated 10 metastases. Vieweg et al. (27) describe 13 patients treated in the period of 8 years for 6 metastases, 3 plasmocytomas, 2 chordomas, one aneurysmatic bone cyst and one histiocytosis.

The anterior approach to the cervical spine is used relatively less frequently while the posterior surgical approach is suitable for most diseases of this part of the spine. Transoral approach is a classical anterior approach to the upper cervical spine suitable for decompression of the spinal cord and the brain stem (9, 16, 19, 22). If the conditions require a more extensive reconstruction or extension of the approach caudally from C3, it is necessary to perform labiomandibulotomy, sometimes in combination with glossotomy (12, 15). A major problem of the transmucous approach are infection complications described by many authors in the literature, and frequent swallowing difficulties (9, 12, 15, 16, 19, 22). Recommended for extensive resection procedures are at present mainly extramucous surgical approaches or a transmandibular circumglossal retropharyngeal approach. DeMonte et al. (8) used the transmandibular circumglossal retropharyngeal approach in 4 patients with a chordoma of the clivus. They report several complications, liquorrhea in two cases, neuropathy in the region of the tongue also in two cases, one defect of both the soft and hard palates and one paresis of the abducent nerve. Mc Afee et al. (18) described retropharyngeal prevascular approach to the upper cervical spine based on the approach presented by De Andrade and Macnab (7). The difference is in a more

extensive anatomical dissection. Retropharyngeal prevascular approach is used in similar indications as the transoral approach and may replace it to a great extent. The advantage is a lower risk of infection and the possibility to extend the approach below C3 without the necessity to perform mandibulotomy (12, 15). The most frequent complication is lesion of the hypoglossal nerve and the facial nerve resulting from overstretching or incautious dissection. Whitesides and Kelly (28) described the retropharyngeal retrovascular approach that they developed by extending the original approach to the carotid artery. Retropharyngeal retrovascular approach is suitable particularly for fixation of the atlantoaxial joints by screws from the lateral side and may be used in indications similar to the two approaches mentioned above. Extensive anterior decompression and reconstruction of the anterior column including internal fixation from this approach is, however, very difficult if not impossible. Described were also complications resulting from the lesion of the accessory nerve, the glossopharyngeal nerve, the facial nerve, the hypoglossal nerve, injury to the internal jugular vein and respiratory failure resulting from oedema of the upper respiratory tract (16, 29). Hart et al. (14) described a posterolateral approach with one angled incision for resection of tumour of C1-C2 at the front, when they at the same time performed occipitocervical fixation with a contoured loop.

The term "spondylectomy" denotes the complete surgical removal of all parts of a vertebra which was in the past misinterpreted in the oncological literature as a simple laminectomy and corpectomy. Cohen et al. (5) used the term "total spondylectomy" for removal of the whole C6 vertebra, including the lateral masses and transversal processes. Total en bloc spondylectomy for tumour is described in the literature dealing with the thoracic and lumbar spine. The technique consists in the complete removal of one or more adjacent vertebrae in two pieces, in front of and behind the dural sac. The surgery may be performed from the posterior or combined approach (1, 17, 26). In both cases, after dissection of pedicles, the whole posterior part of the vertebra is removed in one piece, which is followed in the first case by completion of en bloc corpectomy using the Gigli saw with special emphasis on protection of the spinal cord and other soft tissues. After dissection of the roots on one side the vertebral body is rotated around the dural sac to this side. When employing the combined procedure, it is not necessary to dissect the roots and the body is extracted from the front. With en bloc resection, the risk of contamination of surrounding tissues by tumorous cells is minimized, therefore it is from the oncological viewpoint the most suitable procedure (3, 4). In addition, en bloc resection minimizes potential bleeding from the tumour that is difficult to control. En bloc spondylectomy in the region of the cervical spine is not feasible due to the necessity to preserve vertebral arteries and nerve roots. Nevertheless, it is generally known that in selected cases one vertebral artery

may be sacrificed, if the contralateral artery can ensure adequate blood supply (5, 20). However, total en bloc spondylectomy of a cervical vertebra requires according to the definition, resection of both vertebral arteries (5). As mentioned above, total en bloc spondylectomy in the thoracic and upper lumbar region from the posterior approach includes rhizotomy on the side where the vertebral body will be rotated for removal. Nerve roots in the cervical region cannot be sacrificed without a significant functional limitation of the upper limb. Therefore, the most radical procedure in the region of the cervical spine without significant damage to the patient is the total intralesional spondylectomy.

Total spondylectomy of C2 with preservation of vertebral arteries and roots has not been so far described in the literature and there exist only a few works that deal with a similar issue. The only exception is the personal communication of Suchomel et al. from Liberec who performed a similar total spondylectomy of C2 one month before us, however, they proceeded the other way round and for chordoma of C2 they first removed the anterior portion of C2 and part of the anterior arch of C1 from the transoral approach. Subsequently, in one step, they resected the posterior portion of C2 from the posterior approach and performed occipitocervical fixation of C0-C6. The surgery lasted 13 hours. Rhines et al. (20) described en bloc resection of the chordoma of C2-C4 with ligation of one vertebral artery and C2-C4 roots on one side with dens left in situ. They first used the posterior approach to resect the posterior parts of C2-C4 and dissect the roots and subsequently, they performed occipitocervical fixation of C0-T9. In one step, in cooperation with the otorinolaryngological and stomatosurgical team they applied the transmandibular circumglossal retropharyngeal approach described by DeMonte et al. (8). They resected the anterior part of the vertebrae, ligated one vertebral artery and filled the defect with a fibular donor graft placed between C1-C5 and bridged by a plate with screws anchored cranially in the anterior arch of the atlas and dens and distally in the C5 body. Assisted ventilation was used for several weeks due to the patient's respiratory insufficiency and a gastrostomy tube was inserted due to swallowing difficulties. Radiograph taken 17 days postoperatively revealed dislocation of the caudal end of the fibula with pulled out screws. During revision surgery, they removed the graft and the plate and filled the defect with the Harms cage fixed by screws to C1 and the dens, and distally to the C5 body. The patient's swallowing difficulties were persisting even 4 months after the primary surgery. Endoscopic examination showed defect of the pharynx. The authors repaired the defect by lateral pharyngotomy, using a free flap from the forearm. Bailey et al. (2) in their recent study described a similar surgical procedure. They resected a multi-level cervical chordoma en bloc in three steps. The first day, they used the posterior approach to resect and release the posterior portion of chordoma of C1-C3, dissected the roots of C2-C3 on one side and inserted part of the occi-

pitocervical instrumentation in the region of C0-C6. On the second day, with the patient placed on one side they first re-opened the posterior approach and released fixation. Subsequently, using an extensive anterolateral approach they resected the anterior portion of the vertebrae with tumour and dissected one vertebral artery. On the third day, with the patient in the same position, they re-opened both wounds, finished releasing of the resected part of the spine with tumour, completed the occipitocervical fixation and placed tricortical autogenous bone grafts from the iliac crest in the front part of the defect. The whole surgery divided into three days lasted 40 hours and the blood loss was estimated at 4000 ml. Postoperative treatment was complicated by a septic shock and ARDS, swallowing difficulties persisted for 1 year. Cohen et al. (5) described total spondylectomy of C6 for primary osteosarcoma with preservation of roots and vertebral arteries. In the first step, they resected the posterior part of C6 and fixed C3-T3. One week later they removed the tumour from the front, filled the defect with the Harms cage and bridged by plate. Sar and Eralp (21) described transoral resection of the anterior part of C2, also for a primary osteosarcoma. They filled the defect with the Harms cage without plate. In the second step, again after one week, they resected the posterior part of the vertebra and performed occipitocervical fixation of C0-C4. Vertebral arteries and roots are not mentioned in this study.

Other studies describe incomplete resections of cervical vertebrae (6, 10, 26, 27). Vender et al. (26) performed 7 corpectomies of C2 from the retropharyngeal approach for different diagnoses. They filled the defect with a shaped autogenous bone graft from the iliac crest and bridged it with a plate with screws inserted into C1-C3. For different tumours of the upper cervical spine, Vieweg et al. (27) performed anterior resection of the tumour in 9 cases, posterior resection in three cases and a combined anteroposterior resection in one case. For stabilization they used in most cases a combined fixation of a plate with a graft at the front and a separate Magerl transarticular fixation at the back or in combination with occipitocervical fusion. In 4 cases they considered sufficient to use only anterior stabilization. Fournay et al. (10) performed occipitocervical fixation for metastases in the upper cervical spine in 19 patients. The main goal of these surgical procedures is to limit the pain and prevent or improve the neurological lesion.

Most of similar surgical techniques begin with anterior approach (6, 20, 21), only Cohen et al. (5) started from the posterior approach, the same as we did. If the lesion is not caused by pressure from the front, then in our view, it is more beneficial to use the posterior approach as the first, because fixation of screws and rods in the posterior part is much more stable. Disadvantages of this procedure include a rigid cervical spine, craniocervical junction or both after instrumented spondylodesis from the anterior surgical approach. A short fixation without occipitocervical fusion allows to pre-

serve motion in the atlanto-occipital articulation, however, it can be used only in case of a sufficient fixation of the screws in the atlas, in young patients with a good bone quality. Nevertheless, fixation is always only temporary and therefore it is necessary to put significant emphasis on the bone fusion, in our view preferably by autologous bone grafts. In general, anterior extramucous surgical approach is preferred in extensive resections (7, 8, 16, 18, 20). With regard to the intended extent of resection we used in our case the midline approach with a full cognizance of all potential risks. Similarly as other authors, also we could not avoid serious complications that substantially prolonged the period of hospitalization (2, 20). In spite of this, the short-term result is very satisfactory and the patient is satisfied. But it will be only the follow-up checks that will show how radical our surgical procedure was.

CONCLUSION

Total spondylectomy of C2 with preservation of vertebral arteries and roots stabilized only by a short fixation is an extreme surgical procedure suitable only for exceptional cases of young patients with a good bone quality. With regard to potential complications it is of vital importance to consider carefully such operation and consult the proposed therapy with the patient.

ZÁVĚR

Podle dostupných pramenů nebyla dosud v literatuře popsána totální spondylectomie C2 se zachováním kořenů, zachováním vertebrálních arterií a krátkou fixací bez okcipitocervikální fúze.

U 27letého pacienta se solitární metastázou adenokarcinomu štítné žlázy jsme se rozhodli pro tento radikální operační výkon. Jako první jsme zvolili zadní operační přístup, pacienta jsme uložili v pronační poloze na standardní operační stůl a vypodloženou hlavu jsme fixovali náplastmi v mírném předklonu horní krční páteře. Řezem ve střední čáře od protuberantia occipitalis externa po spinózní výběžek C7 jsme pronikli k páteři, stavěli obvyklé krvácení a skeletizovali v rozsahu C0-C4. Následně jsme resekovali celou zadní část epistropheu včetně většiny pediklů a celé kloubní výběžky pro skloubení C2-C3. Oba kořeny C2 jsme zachovali,

museli jsme však stavět poměrně masivní krvácení z venózního plexu kolem levého kořenu. V průběhu preparace došlo k poranění durálního vaku v oblasti odstu- pu levého kořenu, které jsme řešili suturou a krytím tká- ňovým lepidlem Tissucol. Do laterálních mas atlasu jsme zavedli 4mm šrouby technikou podle Harmse a dále 4mm šrouby do kloubních výběžků C3 a C4. Fixační prvky jsme spojili na obou stranách tyčkami s průměrem 3,2 mm a obě strany potom příčným stabi- lizátorem. Ke stabilizaci jsme použili instrumentaci Vertex. Odebrali jsme spongiózní štěpy z lopaty kosti kyčelní a provedli mohutnou posterolaterální a zadní dēju C1–C4. Druhý operační výkon jsme provedli s odstupem 21 dní. Zvolili jsme transorální transman- dibulární přístup bez rozpolcení jazyka. Pacienta jsme uložili v supinační poloze s podložením krku na stan- dardní operační stůl, hlavu jsme fixovali v mírném záklonu náplastmi a zavedli tracheostomii. Kožní řez jsme vedli v červeni rtu obloukovitě uprostřed, dále 2 cm rovně kaudálně a opět obloukovitě přes bradu na krk ve střední čáře. Na kaudálním konci jsme provedli příčnou incizi ve tvaru obráceného „T“. Následně jsme ve střední čáře skeletizovali mandibulu a osteotomova- li ve střední čáře ve tvaru „Z“. Zavedli jsme rámový rozvěrač Synframe, jedna lopatka rozvířala ústa tlakem na horní zuby, dvě lopatky tlačili na jazyk kaudálně, tak jsme ozřejmili prostor mezi předním obloukem C1 a tělem C4. V mukóze jsme provedli incizi ve tvaru obráceného „U“ a ozřejmili paravertebrální svaly. Zavedli jsme Casparův rozvěrač, oddělili svaly a ske- letizovali C1–C3 laterálně včetně transverzálních výběžků s vertebrálními arteriemi. Na skeletu nebyly patrné patologické změny. Nejprve jsme odstranili střední část těla C2, kde jsme nenalezli tumor, pouze sklerotickou přestavbu. Následně jsme odfrézovali dol- ní střední část předního oblouku C1, vytáhli dens a odřízli lig. alaria a lig. apicis dentis, dens jsme potom vcelku vyjmuli. Pokračovali jsme vpravo, ve zdravé čás- ti a odstranili část C2 v oblasti atlantoaxiálního kloubu včetně zbytku pediklu a přední část processus trans- versus až po vertebrální arterii. Zadní část transverzál- ního výběžku jsme vytočili kolem arterie a rovněž odstranili. Všechny části byly extrémně tvrdé, sklero- tické. Shodně jsme postupovali vlevo, kde jsme nalez- li v laterální části C2 pod atlantoaxiálním kloubem gela- tinózní šedavý tumor velikosti 7x10 mm, ostatní části byly opět sklerotické. Při preparaci kolem kořenu C2 vlevo opět došlo k likvoree, jejíž zdroj jsme nedokáza- li jednoznačně identifikovat. Místo pravděpodobného otvoru jsme zalili tkáňovým lepidlem Tissucol. Dále jsme mezi zářez ve spodní části předního oblouku C1 a horní krycí plochu těla C3 vzepřeli formonavou klec SynMesh s ostrými okraji, držení bylo velmi dobré, pří- datnou fixaci jsme neprováděli. Opět jsme odebrali spongiózní štěpy z lopaty kosti kyčelní a aplikovali je kolem klece laterálně a vpředu mezi předním obloukem atlasu a tělem C3. Následně jsme sblížili svaly a repa- rovali mukózní tkáň faryngu. Osteosyntézu mandibuly jsme provedli dvěma dlahami Miniplate System a zaji- stili dentální dlahou.

Totální spondylektomie C2 se zachováním verte- brálních arterií a kořenů zajištěná pouze krátkou fixací je extrémní operační výkon vhodný pouze ve výjimeč- ných případech u mladých pacientů s dobrou kvalitou kosti. Vzhledem k možným komplikacím je nutné vždy pečlivě zvážit benefit takového výkonu a navrhovanou terapii pečlivě konzultovat s pacientem.

Literatura

1. ABE, E., SATO, K., TAZAWA, H., MURAI, H., OKADA, K., SHIMADA, Y., MORITA, H.: Total spondylectomy for primary tumor of the thoracolumbar spine. *Spinal Cord*, 38: 146–152, 2000.
2. BAILEY, Ch. S., FISHER, Ch., G., BOYD, M. C., DVORAK, M. F. S.: En bloc marginal excision of a multilevel cervical chordoma. *J. Neurosurg. Spine*, 4: 409–414, 2006.
3. BORIANI, S., BANDIERA, S., BIAGINI, R., BACCHINI, P., BORIANI, L., CAPPUCCIO, M., CHEVALLEY, F., GASBARRINI, A., PICCI, P., WEINSTEIN, J. N.: Chordoma of the Mobile Spine: Fifty Years of Experience. *Spine*, 4: 493–503, 2006.
4. BORIANI, S., CHEVALLEY, F., WEINSTEIN, J. N., BIAGINI, R., CAMPANACCI, L., DE IURE, F., PICCILLI, P.: Chordoma of the Spine Above the Sacrum: Treatment and Outcome in 21 Cases. *Spine*, 13: 1969–1977, 1996.
5. COHEN, Z. R., FOURNEY, D. R., MARCO, R. A., RHINES, L. D., GOKASLAN, Z. L.: Total cervical spondylectomy for primary osteogenic sarcoma. *J. Neurosurg. Spine*, 97: 386–392, 2002.
6. COLAK, A., KUTLAY, M., KIBICI, K., DEMIRCAN, M. N., AKIN, O. N.: Two-staged operation on C2 neoplastic lesions: anterior excision and posterior stabilisation. *Neurosurg. Rev.*, 27: 189–193, 2004.
7. De ANDRADE, J. R., MACNAB, I.: Anterior occipito-cervical fusion using an extrapharyngeal exposure. *J. Bone Jt Surg.*, 51-A: 1621–1626, 1969.
8. De MONTE, F., DIAZ, E. Jr., CALLENDER, D., SUK, I.: Trans- mandibular, circumglossal, retropharyngeal approach for chordomas of the clivus and upper cervical spine. *Neurosurg. Focus*, 10: 1–5, 2001.
9. FANG, H. S., ONG, G. B.: Direct anterior approach to the upper cervical spine. *J. Bone Jt Surg.*, 44-A: 1588–1604, 1962.
10. FOURNEY, D. R., YORK, J. E., COHEN, Z. R., SUKI, D., RHINES, L. D., GOKASLAN, Z. L.: Management of atlantoaxial metastases with posterior occipitocervical stabilization. *J. Neurosurg. Spine*, 98: 165–170, 2003.
11. GEORGE, B., ARCHILLI, M., CORNELIUS, J. F.: Bone tumors at the cranio-cervical junction. Surgical management and results from series of 41 cases. *Acta Neurochir.*, 148: 741–749, 2006.
12. HALL, J. E., DENIS, F., NURRAY, J.: Exposure of the upper cervical spine for spinal decompression by a mandible and tongue splitting approach. Case report. *J. Bone Jt Surg.*, 55-A: 121–123, 1977.
13. HARMS, J., MELCHER, P. R.: Posterior C1–C2 Fusion With Polyaxial Screw and Rod Fixation. *Spine*, 26: 2467–2471, 2002.
14. HART, R. A., WEINSTEIN, J. N., MENEZES, A. H.: Posterola- teral approach for anterior resection and posterior stabilisation of the upper cervical spine: a case report. *Iowa Orthop. J.* 16: 157–160, 1996.
15. HONMA, G., MAROTA, K., SHIBA, R., KONDO, H.: Mandibu- le and tongue splitting approach for giant cell tumor of axis. *Spine*, 14: 1204–1210, 1989.
16. LAUS, M., PIGNATTI, G., MALAGUTI, M., CALOGERO, A., ZAPPOLI, F., GIUNTI, A.: Anterior Extraoral Surgery to the Upper Cervical Spine. *Spine*, 14: 1687–1693, 1996.

17. MARMOR, E., RHINES, L. D., WEINBERG, J. S., GOKASLAN, Z. L.: Total en bloc lumbar spondylectomy. *J. Neurosurg. Spine*, 95: 264–269, 2001.
18. McAFEE, P. C., BOHLMAN, H. H., RILEY, L. H., ROBINSON, R. A., SOUTHWICK, W. O., NACHLAS, N. E.: The anterior retropharyngeal approach to the upper part of the cervical spine. *J. Bone Jt Surg.*, 69-A: 1371–1383, 1987.
19. MUMMANENI, P. V., HAID, R. W.: Transoral Odontoidectomy. *Neurosurgery*, 5: 1045–1050, 2005.
20. RHINES, L. D., FOURNEY, D. R., SIADATI, A., SUK, I., GOKASLAN, Z. L.: En bloc resection of multilevel cervical chordoma with C2 involvement. *J. Neurosurg. Spine*, 2: 199–205, 2005.
21. SAR., C., ERALP, L.: Transoral Resection and Reconstruction for Primary Osteogenic Sarcoma of the Second Cervical Vertebra. *Spine*, 17: 1936–1941, 2001.
22. SHAHA, A. R., JOHNSON, R., MILLER, J., MILHORAT, T.: Transoral- transpharyngeal Approach to the Upper Cervical Vertebrae. *Amer. J. Surg.*, 4: 336–340, 1993.
23. STRAYER, A.: Upper Cervical Spine Chordoma: A Case Study. *J. Neurosci. Nurs.*, 5: 276–280, 2003.
24. SUNDARESAN, N., KROL, G., SEN, C.: Spinal chordomas. In: Wilkins, R., Rengachary, S. (eds.): *Neurosurgery*. New York, McGraw-Hill 1996, 1815–1825.
25. ŠTULÍK, J., ŠEBESTA, P., VYSKOČIL, T., KRYL, J.: Atlantoaxial fixation using the polyaxial screw-rod system. *Europ. Spine J.*: v tisku
26. TOMITA, K., KAWAHARA, N., BABA, H., TSUCHIYA, H., FUJITA, T., TORIBATAKE, Y.: Total En Bloc Spondylectomy: A New Surgical Technique for Primary Malignant Vertebral Tumors. *Spine*, 3: 324–333, 1997.
27. VENDER, J., HARRISON, S. J., McDONNELI, D. E.: Fusion and instrumentation at C1-3 via the high anterior cervical approach. *J. Neurosurg. Spine*, 92: 24–29, 2000.
28. VIEWEGH, U., MEYER, B., SCHRAMM, J.: Tumour Surgery of the Upper Cervical Spine – A Retrospective Study of 13 Cases. *Acta Neurochir.*, 143: 217–225, 2001.
29. WHITESIDES, T. E., JR, KELLY, R. P.: Lateral approach to the upper cervical spine for cervical fusion. *S. Med. J.*, 59: 879–883, 1966.
30. WOOD, B. G., SADAR, E. S., LEVINE, H. L., DOHN, D. F., TUCKER, H. M.: Surgical problem of the base of the skull. *Arch. Otolaryngol.*, 106: 1–5, 1980.

Ass. Prof. Jan Štulík, MD. PhD.,
Department of Spinal Surgery, University Hospital Motol,
V Úvalu 84,
150 06 Prague 5

Práce byla přijata 21. 12. 2006.
Barevná dokumentace byla dotována.