

# Extending the Indications of Intramedullary Nailing with the Expert Tibial Nail®

## Rozšířené indikace nitrodřeňového hřebování tibiálním hřebem Expert

S. KUHN<sup>1</sup>, M. HANSEN<sup>2</sup>, P. M. ROMMENS<sup>1</sup>

<sup>1</sup> Department of Trauma Surgery, University Hospital of the Johannes Gutenberg-University of Mainz, Germany

<sup>2</sup> Clinic for Trauma, Hand and Reconstructive Surgery, City Hospital, Worms, Germany

### SUMMARY

Numerous modifications in nail and screw design have led to the development of the Expert Tibial Nail®. It enables the surgeon to further extend the spectrum of fractures eligible for intramedullary nailing. In the proximal metaphysis spongious bone screws achieve an optimized purchase in the cancellous bone. Multidirectional interlocking screws ensure that alignment can be well maintained and stability preserved in short proximal or distal tibial segments. The end cap achieves angular stability between the proximal oblique screw and the nail. These changes in implant design enhance the stability of the bone-nail construct and reduce the risk for secondary malalignment. The results of our prospective case series demonstrate favorable results and extended indications, compared to standard tibial nails.

### INTRODUCTION

The Expert Tibial Nail® (ETN®, Synthes®) was introduced worldwide in 2005 as a universal intramedullary implant for tibial fractures. Several technical modifications compared to standard tibial nails were incorporated in the design. The numerous multiplanar locking options at the proximal and distal end allow for secure stabilization of metaphyseal fragments. Certain intra-articular tibial fractures can be addressed by intramedullary nailing in combination with other implants. Results from the prospective clinical evaluation compare favorably to the use of standard nails.

#### Development of the Expert Tibial Nail®

Due to the technical limitations of the available implants such as the Unreamed Tibial Nail® (UTN®, Synthes®) for the stabilization of metaphyseal fractures, new intramedullary tibial implants have been developed.

As a first result the Proximal Tibial Nail® (PTN®, Synthes®) was designed and clinical investigation was started in 1999. The nail was available in 200 mm or 240 mm versions and featured an optimized geometry for the proximal tibia. For the first time it offered proximal locking options in three different planes with near angular stability of the nail-screw construct. Cancellous bone screws with a double thread and an enlarged 5.1 mm core led to an optimized purchase within the trabecular bone of the proximal metaphysis (Figure 1A). Hansen et al showed excellent clinical results in the treatment of proximal tibial fractures (Figure 1B and 1C).

In their prospective clinical study only one out of the thirteen patients who were treated primarily by intramedullary PTN nailing showed a secondary malalignment greater 3° in any plane (21).

The good clinical results of the PTN® led to the design of a universal tibial intramedullary implant. The Tibial Nailing System® (TNS®) was a prototype implant, which displayed most of the design features later found in the Expert Tibial Nail®. The proximal multidirectional interlocking of the PTN® was incorporated in addition to the standard medio-lateral locking options (Figure 2A). Distally four multidirectional locking options were available (Figure 2B). The prospective multicentric clinical study was conducted in 2004. Our hospital contributed twenty-eight documented cases. Postoperatively two patients displayed a primary malalignment. Eighteen of the twenty-eight patients were followed until union. None of these patients displayed a secondary malalignment (33).

Due to combined results from the different study centers the prototype nail was modified by adding a 2° incline to the 8° proximal nail radius for easier insertion and a better fit in the intramedullary canal (Figure 2C).

The modified nail became the Expert Tibial Nail®. In 2004/2005 our hospital took part in the multicenter clinical trial. Twenty-nine patients were included from our hospital. One patient with a 41 A3 fracture displayed postoperatively a primary varus and antecurvature malalignment. Twenty-four patients were followed up until union. No secondary malalignment occurred (41).

The ETN was introduced by Synthes worldwide in 2005 as a universal tibial intramedullary implant.

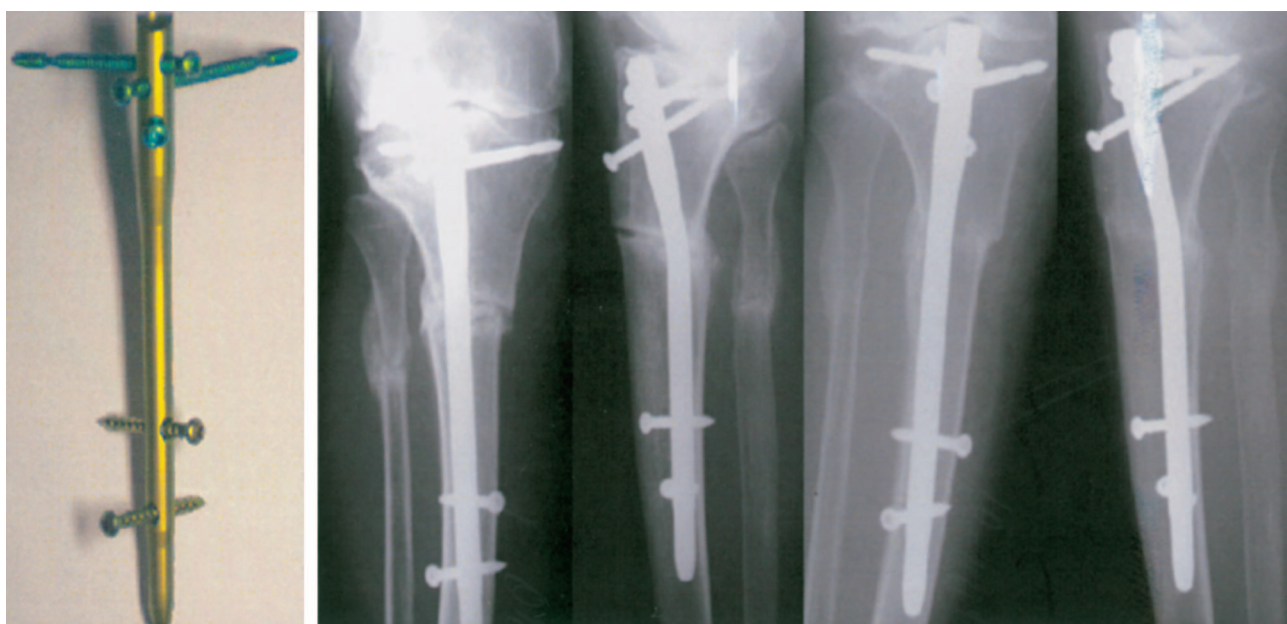


Figure 1. A: Proximal Tibial Nail® (PTN®, Synthes®); B: Postoperative a.p. and lateral x-rays demonstrate unreamed intramedullary nailing; C: A.p. and lateral radiographs at the time of bony union show an anatomical alignment.




Figure 2. A: Proximal locking options with spongius (gold) and standard locking screws (blue); B: Distal locking options with standard screws; C: TNS® with „Herzog“ bend of 8°.

### Technical Aspects and scientific background of the design of the Expert Tibial Nail®

#### • Nail design

The Expert Tibial Nail® is an intramedullary implant made of titanium alloy (TAN) for improved mechanical and fatigue resistance properties (Figure 3). Depending on the anatomical situation, nail lengths between 255 mm and 465 mm are available in 15 mm steps. There is a solid version (8, 9 and 10mm diameter) for an unreamed surgical technique. The cannulated version (8 mm to 13 mm diameter), which enables nail inser-

tion over a guide wire, can be used for reamed or unreamed techniques.

Based on anatomical CT morphometric studies the ETN® features an optimized geometry at its proximal end. Additional to an 8° radius of the proximal part a 2°incline allows easier insertion and extraction of the nail.

The location and degree of the “Herzog” bend influences nail insertion and nail stability. Henley et al. analyzed the wedge effect of the UTN® on the distal segment with subsequent posterior translation, supporting the use of a nail with a proximal bend (22).

#### • Proximal locking options

For proximal locking a total of five options are possible (Figure 4). Two conventional medio-lateral locking options allow primary compression and secondary dynamisation. In addition three locking options for cancellous bone locking screws at the far proximal end led to an optimised stabilization of the proximal tibial fragment with close to angular stability.

Henley et al. compared the biomechanical properties of paired oblique locking screws versus paired transverse screws for stabilization of proximal tibia fractures. The oblique locking screws decreased medial-lateral translation significantly compared with the use of two parallel screws. Furthermore they showed a decrease in varus-valgus angulation and rotation (22).

In a biomechanical study Laflamme et al. showed that the addition of two proximally placed oblique screws




Figure 3. Expert Tibial Nail® (ETN®, Synthes®).




Figure 4. Proximal locking options with spongius (gold) and standard locking screws (blue).

3 | 4 | 5

Figure 5. Distal locking options with standard locking screws.




Figure 6. A: Spongius locking screw (gold); B: 4.0 mm standard locking screws (blue); C: 5.0 mm standard locking screws (green).

significantly enhanced the stability of the construct compared to two transverse screws. In varus-valgus and flexion-extension, the appendage of oblique screws increased the stability by approximately 50% (30).

In a biomechanical model, Hansen et al. were able to demonstrate superior stability of the proximal interlocking configuration found in the ETN®/PTN® compared to a traditional interlocked nail which was augmented by a mounted and fixed small transverse plate (so called “Mickey Mouse” plate). Their prospective Proximal Tibial Nail clinical study proved the practical relevance of the construct (17, 21).

• **Distal locking options**

At the distal end the ETN® features four locking options (Figure 5). Two medio-lateral (at 37 resp. 13 mm from the nail tip) and one antero-posterior locking op-

tion (22 mm from the nail tip) provide a secure stabilization. One oblique hole located at 5 mm from the nail tip allows for the fixation of hard to reach very distal fracture fragments.

Prior to the introduction of modern tibial nails, which offer multiple far distal locking options, several authors suggested the use of a shortened standard tibial nail. The nail tip was then cut off to diminish the distance between the most distal interlocking hole and the nail tip.

The stability of intramedullary fixation of distal tibia metaphyseal fractures with shortened nails has been studied biomechanically. Gorczyca et al. analyzed matched pairs of cadaveric tibias, with osteotomies extending 4 cm respectively 5 cm above the tibio-talar joint. Four centimeter long distal tibia fragments stabilized with shortened nails (the distal 1 cm of the nail was removed) had comparable stiffness in compression and tor-





Figure 7. End caps with 0 mm to 15 mm lengthening.

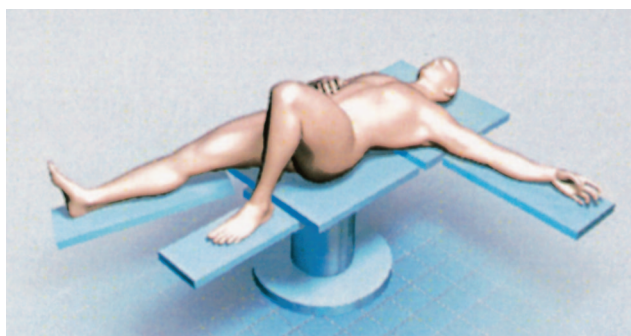

Figure 8. Positioning of the patient.

sion to 5 cm distal tibia fragments instrumented with standard tibial nails (15).

In a biomechanical study George et al. demonstrated that rotational stability of the intramedullary nail-bone construct increases the further the distal interlocking screw is located away from the fracture (14).

In fractures within 30 mm of the plafond Robinson shortened the nail to enable the placement of two interlocking screws in the distal fragment (36).

Dogra et al. retrospectively reviewed fifteen patients with distal tibial fractures treated with similarly modified Grosse-Kempf (Howmedica®) or Russell-Taylor Delta (Smith and Nephew®) reamed tibial nails. Approximately 1 cm of the nail end distal to the lowermost locking hole was removed. Functional outcome was good with all patients able to return to normal daily activity. All fractures united, twelve without incident and three after a secondary surgical procedure including two dynamization cases and one nail exchange and bone grafting. Malalignment, defined as varus-valgus angulation or recurvatum of 5° or greater, was reported in three patients (9).

#### • All Locking screws

All locking screws of the ETN® are made of the titanium alloy TAN for improved mechanical and fatigue resistance properties (Figure 6). They all present a double thread which continues up to the screw head. This leads to enhanced stability due to more contact points at the bolt-nail interface and a better bone purchase of the helix. A self holding Stardrive recess is incorporated in the screw head to secure screw pick-up.

Standard locking screws are available with 4.0 mm diameter for 8 mm and 9 mm tibial nails and 5.0 mm diameter for 10 mm to 13 mm tibial nails. Compared to previous intramedullary implants like the UTN® (Synthes®) all locking screws have a larger core cross section which leads to an improved mechanical resistance.

Cancellous bone locking screws always have a large 5.0 mm cross section. Compared to the standard locking screws they feature a deeper thread, which provides an optimised purchase in cancellous bone. Due to close proximity to neurovascular structures and the proximal tibio-fibular joint these screws must always be introduced monocortical.

While nail breakage is rare, fatigue failure of locking screws was reported with a high incidence of 5% to 50% in the past (16, 43). Whittle showed that half of the patients with screw failure after unreamed intramedullary tibial nailing needed additional procedures to obtain union (43). Court-Brown showed that the high rate of malunion in low diameter unreamed nails was related to the high number of screw breakages (8).

There are three main variables to improve fatigue strength of locking screws: material, core diameter and thread design (13).

As a working material titanium alloys display a significantly higher fatigue strength compared with stainless-steel implants. Their modulus of elasticity is lower making them more flexible, which may have physiological advantages (37).

In static bending tests, the strength of screws varies as the third power of the core diameter. A 2-fold increase in the core diameter will result in an 8-fold increase in bending strength. Gaebler investigated the fatigue strength of locking screws in small-diameter tibial nails and demonstrated that a 20% increase in screw diameter leads to an additional 25% to 70% in fatigue strength (13).

While a non-continuous threaded screw with a solid core at the aperture of the nail displays an improved fatigue strength by optimizing the core diameter of the central segment, it leads to a higher incidence of screw loosening (13). Krag showed that the pull-out strength is primarily affected by the outer diameter and the depth of the screw's thread (26). Additionally a double threaded helix, increases the bolt-nail contact points stabilizing the bolt-nail construct (20).

#### • End caps

The end cap prevents ingrowth of hard and soft tissue thus facilitating hardware removal. When used with the cancellous bone screw locking options the end cap leads to an absolute angle-stable proximal screw-nail construct. End caps are available in four different sizes with the option of lengthening the nail up to 15 mm (Figure 7). The end cap head also features a self-holding Stardrive recess for a secure pick-up.

These changes in nail and screw design enhance the bone-nail construct stability and reduce the risk of secondary malalignment.




Figure 9. A: Determining the nail length; B: Determining the nail diameter.

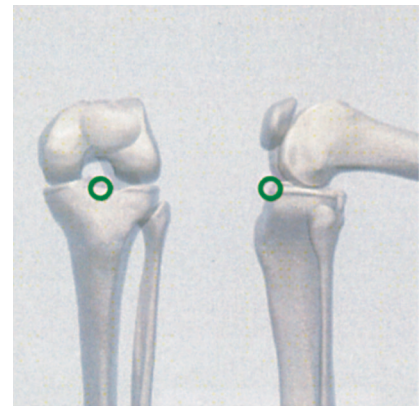


Figure 10. Determining the correct entry point.

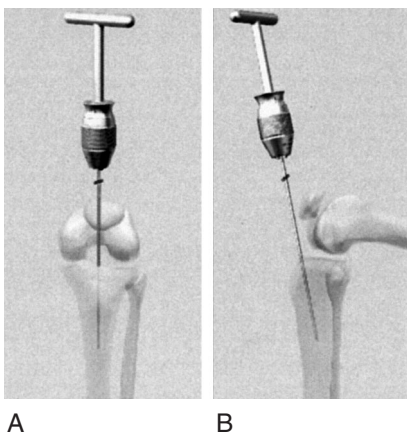


Figure 11. A: Correct position of guide wire in a.p. view; B: Correct position of guide wire in lateral view.

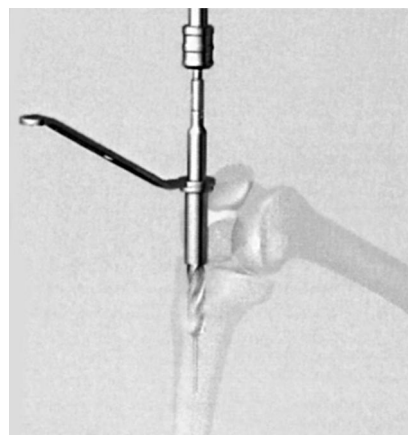


Figure 12. Open the medullary canal using the cannulated drill bit.

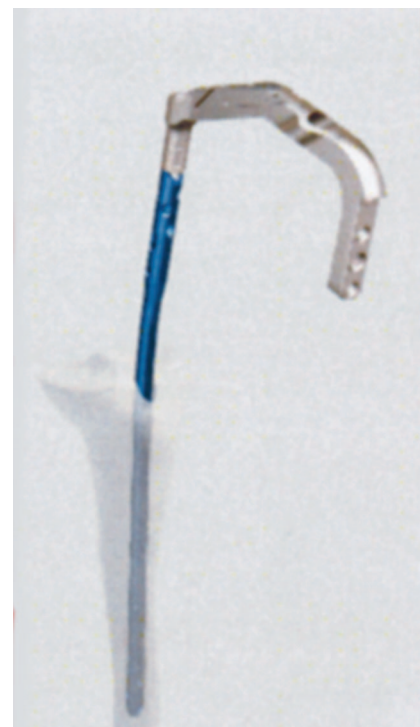

Figure 13. Inserting of the Expert Tibial Nail®.

### Indications for the Expert Tibial Nail®

The Expert Tibial Nail® expands the indications for intramedullary nailing far beyond shaft fractures. The implant is suitable for proximal as well as distal metaphyseal fractures and certain intraarticular fractures of the tibial head and the pilon.

Following the AO Müller classification of fractures, the ETN can be used as a sole implant in the following fracture types and in combinations of these fractures:

- 41-A2/A3
- All fractures of the 42 segment
- 43-A1/A2/A3

Furthermore certain intrarticular fractures of the proximal and distal tibia can be addressed by the ETN® in combination with other implants (e.g. minimal invasive lag screw fixation followed by intramedullary nailing):

- 41-C1/C2
- 43-C1/C2

Besides primary fracture treatment the ETN® can be used in secondary procedures or revision surgery such as non-unions, mal-unions and tumors.

### Surgical technique

- *Position the patient* (Figure 8)

The patient is positioned supine on a radiolucent table. The ability to flex the knee by at least 90° is required.

- *Reduce fracture*

A closed reduction is performed under image intensifier guidance. The reduction can be temporarily fixed with reduction clamps.

- *Determine nail length and diameter* (Figure 9)

The required nail length is determined using the radiographic ruler. The possibility of axial shortening





Figure 14. Confirming the correct proximal nail position.



Figure 15. Confirming the correct distal nail position.




Figure 16. Distal locking.

due to primary compression or secondary dynamisation must be considered when determining the nail length. The locking screw in the dynamic locking option can move up to 7 mm.

- *Incision*

The skin incision has to be in line with the central axis of the medullary canal. Depending on the anatomy of the patient and surgical preference, the incision can be transpatellar, medial or even lateral parapatellar and extends from the inferior third of the patella to the tibial tuberosity.

- *Determine the correct entry point (Figure 10)*

The correct entry point is crucial for the alignment of the ETN®. In the a.p. view the entry point is in line with the axis of the intramedullary canal and with the lateral tubercle of the intercondylar eminence. In lateral view the entry point is at the ventral edge of the tibial plateau.

- *Insertion of the guide wire (Figure 11)*

Insert the guide wire for approximately 8–10 cm. It should be in line with the medullary canal on the a.p. view and at a 10° angle to the shaft axis in the lateral projection.

- *Open the medullary canal (Figure 12)*

There are several options for opening the medullary canal including the cannulated drill bit, the cannulated awl, or the cutter. With any method the medullary canal should be opened over 8–10 cm. Further the instruments must not touch the posterior tibial cortex.

- *Reaming (optional)*

If desired the medullary canal can be enlarged by reaming.

- *Insertion of the nail (Figure 13)*

The ETN® is introduced with the knee in at least 90° flexion using the insertion handle and slight rotational movements. The passage of the nail through the fracture site should be closely monitored and the final position confirmed using the image intensifier.

- *Confirm proximal nail position (Figure 14)*

After attaching the aiming arm the correct proximal position can be confirmed with a guide wire. Consideration must be given if primary compression or secondary dynamisation is planned. The locking screw in the dynamic locking option can move by up to 7 mm.

- *Confirm distal nail position (Figure 15)*

Confirm distal positioning in a.p. and lateral views.

- *Distal locking (Figure 16)*

In 8 and 9 mm diameter nails 4.0 mm locking screws are used. In 10 to 13 mm nails 5.0 mm locking screws are utilized. Usually distal locking is carried out first since this enables to reduce a present diastasis. In proximal or diaphyseal lesions distal interlocking with two medio-lateral screws is sufficient. However in distal tibial fractures three or four screws are recommended to achieve adequate stability.

- *Proximal locking*

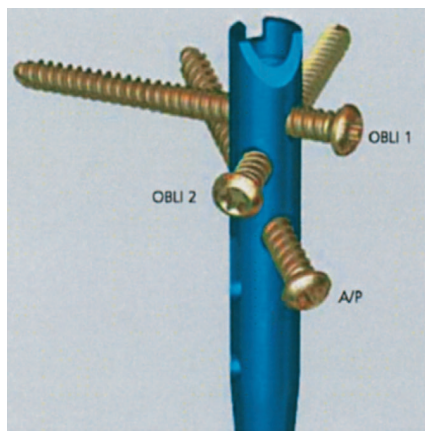
For proximal locking it is recommended to extend the leg in order to relax the muscles acting as a dislocating factor on the proximal tibial segment. Medio-lateral locking is used for diaphyseal fractures. Proximal oblique locking is preferred in more proximal tibial fractures.

- *Proximal medio-lateral locking (Figure 17)*

In 8 and 9 mm diameter nails 4.0 mm locking screws are used. In 10 to 13 mm nails 5.0 mm locking screws

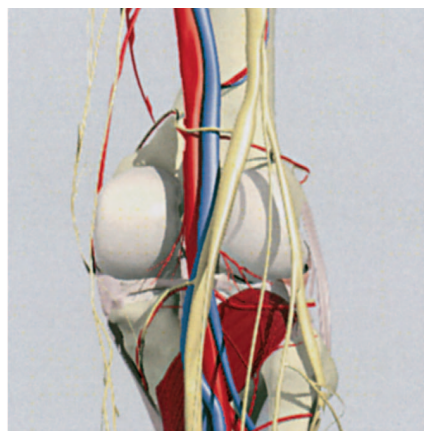


Figure 17. Proximal medio-lateral locking with standard locking screws.



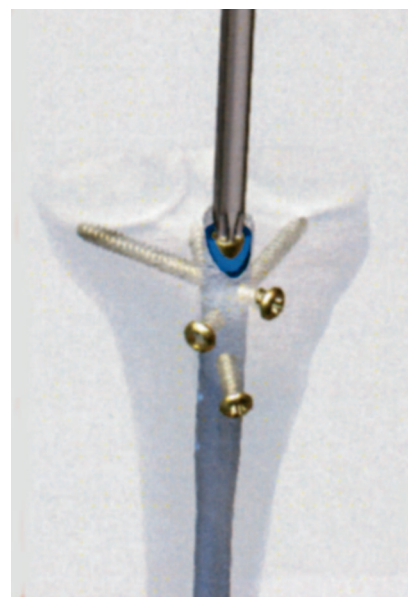A

Figure 18. A: Proximal oblique locking; B: Neurovascular structures. ▲



B

Figure 19. Inserting the end cap. ►



are utilized. The dynamic locking option allows primary compression or secondary dynamisation. Using the compressing screw, up to 7 mm of compression can be achieved. If more compression is necessary the back-strike technique is used. The fracture gap has to be monitored radiographically during the procedure.

- *Proximal oblique locking (Figure 18A)*

For proximal oblique locking all nails utilize the 5.0 mm cancellous locking screws. Drilling and introduction of the screw must be strictly monocortical to avoid lesions of the popliteal artery, the tibial and common peroneal nerves and injuries to the proximal tibiofibular joint (Figure 18B).

- *Insertion of the end cap (Figure 19)*

Besides preventing ingrowth of soft tissue and bone into the nail, the end cap gives the option of achieving angular stability between the proximal oblique screw and the ETN. Angular stability can also be achieved between the second oblique locking option and the nail when leaving the most proximal oblique locking option empty and using the special end cap. If needed, four different size end caps allow a lengthening of the nail by up to 15 mm.

### **Intramedullary nailing of metaphyseal tibial fractures**

For years closed intramedullary nailing has been the preferred method of surgical treatment for closed and grade I open fractures of the tibial diaphysis (3, 4, 10, 39). Satisfactory clinical results with a low rate of complications have been reported in many studies (2, 5, 7). However, the optimal method of treatment in the metaphyseal regions and in open fractures remains debatable. The introduction of interlocking tibial nails has

extended the indications for intramedullary fixation to include fractures that are within the proximal and distal metaphysis. However, clinical studies in the past have demonstrated a high incidence of malalignment after intramedullary osteosynthesis in metaphyseal fractures, especially proximal ones (1, 12, 31).

Freedman and Johnson retrospectively studied 133 fractures of the tibia treated by intramedullary nailing. Malalignment was seen in 58% of fractures of the proximal third (12). Lang et al. documented 5° of angulation in at least one plane in 84% of the cases of proximal tibial fractures treated by intramedullary nailing. Additionally 59% of the treated fractures presented 10 mm or more of displacement (31). Similar results were found in our own clinical data published by Ahlers and von Issendorf as well as Hansen (1, 12, 31). As a result clinicians have been reluctant to treat these fractures with intramedullary nailing.

Many challenges in nailing metaphyseal tibial fractures arise from the anatomy of these segments. The diameter of the medullary cavity increases in the proximal and distal segment, forming an hourglass-shape. Unli-






Figure 20. „Toggeling“ of the interlocking screws.

ke in tibial shaft fractures, where the close contact between the nail and the medullary canal assists the alignment, the different anatomy in the metaphysis provides little stability for the bone-nail construct.

Towards the metaphysis, the tibial cortex becomes thinner and is centrally replaced by metaphyseal secondary spongiosa and cancellous bone. In young patients, this cancellous bone is usually dense, providing good purchase for the blocking screws. With age the microstructure of the bone changes, resulting in an increased distal canal diameter and a decreased cancellous bone density. This further lessens the nail-cortex contact and screw purchase (38).

Other challenges are based on the implants design. Traditional tibial nails offer only a limited number of locking options, which usually consists of two proximal (one static, one dynamic) and two distal ones. All locking options feature the same orientation in the frontal plane. Due to the positioning of these locking screws in respect to the distance to either nail end, they cannot secure remote proximal or distal fracture segments. The design of the screws, with a relatively low cross section, low profile thread and only single threaded layout achieves only a weak purchase in the cancellous bone. Due to the mismatch of the screws and nail locking options, there is a relative instability, which can result in “toggeling” of the screws and subsequent dislodgement (Figure 20).

In conclusion we can say that traditional nails offer only a limited stability of the bone-nail construct outside of the tibial shaft fractures, which can lead to a secondary dislocation.

- *Proximal metaphyseal fractures*

Good results can be obtained with intramedullary nailing of proximal tibial fractures, but they require close attention to detail to avoid primary and secondary malalignment. Several technical modifications of the standard intramedullary nailing technique have been

described in the past decade. Most improvements are based on changes in the operative reduction technique and improvements of the implant design.

To achieve an optimal reduction of fractures of the proximal third, the nail must be in line with the central axis of the proximal and distal tibial fracture fragments. Several authors have suggested modifications to the entry point. Henley advised a proximal starting point, while Freedmann and Lang recommended a lateral entry (12, 22). Buehler et al. advised a lateral starting point with the additional use of a femoral distractor.

Before reducing the fracture and introducing the nail, the femoral distractor is temporarily applied to counteract the deforming forces during nail insertion (6). We recommend as an ideal entry point the part of the ventral edge of the tibial plateau, which is in line with the axis of the intramedullary canal and with the lateral tubercle of the intercondylar eminence.

A number of modifications to the surgical approach have been recommended. To reduce apex anterior angulation of the proximal fragment Tornetta and Collins suggested lateral subluxation of the patella and positioning the knee in a semi-extended position during nail introduction, to avoid deforming factors caused by patella tendon strain. Their clinical study showed good results at the time of union with no patient presenting anterior angulation greater 5° and only two of the twenty-five treated fractures malaligned in more than 5° of angulation in any other plane (42).

To address varus-valgus instability in proximal tibial fractures, Krettek et al. investigated the use of Poller screws placed adjacent to the nail to decrease the size of the medullary canal and reduce nail translation. In everyday practice, Poller screws are applied primarily as a reduction tool and secondarily to decrease instability. However, they have also proven to be effective in maintaining alignment. In their biomechanical model, the use of Poller screws increased stability to the intramedullary nail with two locking screws by 25% in the sagittal plane (27). Krettek et al. were also able to show in a prospective clinical study with ten proximal and eleven distal tibia fractures an average coronal and sagittal plane deformity of less than 2° (28). Ricci et al. included only patients with proximal tibial fractures who were treated by intramedullary nailing and Poller screws. In all cases malalignment was less than 5° in any plane postoperatively and at the time of union (35).

In our view, the major advancement in intramedullary nailing of proximal tibial fractures was the introduction of modern implants with several multiplanar locking options. The ETN® offers a total of five proximal locking options. In proximal metaphyseal fractures the use of the three spongy locking screws ensures optimal stabilization of the proximal fragment. The end cap provides angle stable locking of the proximal locking screw. In certain fracture types additional use of the medio-lateral screws may add to the stability. Thanks to changes in proximal locking options the incidence of secondary malalignment is significantly decreased.



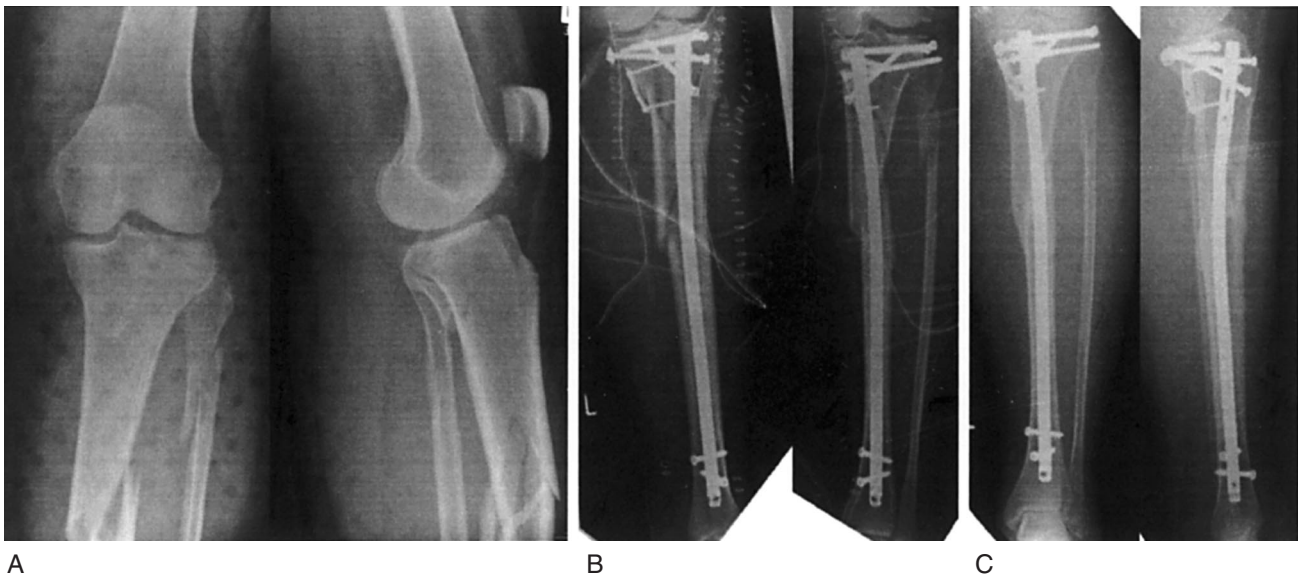


Figure 21. A: A 53-year old female sustained a combined intraarticular and segmental shaft fracture of the tibia (41C1 and 42C1). B: Stabilization was performed with a lag screw fixation and plate osteosynthesis for the intraarticular component and followed by intramedullary nailing with an Expert Tibial Nail for the metaphyseal-diaphyseal component. C: Radiographs at thirteen months post trauma show the healed tibial fractures in anatomical alignment. The patient has a good clinical outcome.

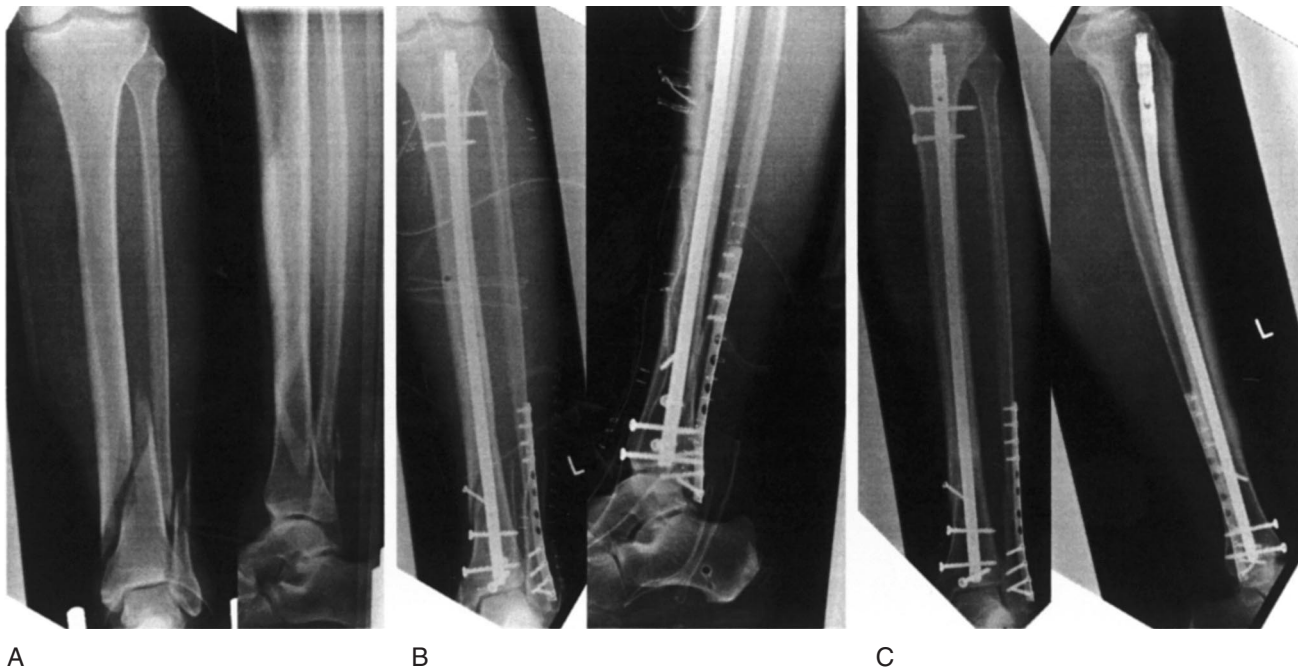


Figure 22. A: A 66-year old male sustained an II° open complete lower leg fracture in a motorcycle accident. B: Three days after primary stabilization with a bridging external fixator, intramedullary nailing with an additional lag screw fixation was carried out. To ensure secure fixation 4 distal locking bolts were used. C: Radiographs at one year show the healed tibial fracture in anatomical alignment.

However special attention has to be given to the specific anatomy of the proximal lower leg. Drilling and introduction of the screws must be strictly monocortical to avoid lesions of the popliteal artery, the tibial and common peroneal nerve and injuries to the proximal tibiofibular joint (19, 24).

• *Distal metaphyseal fractures*

In distal tibial fractures two different entities have to be clearly differentiated. First, distal metaphyseal fractures, which are defined by the primary fracture being located in the metaphysis, with or without simple articular extension. Second, pilon fractures which

primarily involve the ankle joint with or without substantial articular displacement and possible metaphyseal compromise. It is of great relevance to understand the difference since treatment principles for these fractures differ from each other completely. In clinical practice, it can be difficult to select candidates with simple articular extension eligible for intramedullary fixation from patients with pilon injuries, which require ORIF.

Proximity to the ankle joint amplifies the bending moment of the distal segment and may facilitate fracture propagation into the ankle joint (36, 40). Failure to control the distal fragment or eccentric reaming can lead to significant primary malalignment.

Unlike nailing of a tibial diaphyseal fracture, nail insertion in a distal metaphyseal fracture does not result in fracture reduction. Therefore, careful control of the distal fragment is critical while introducing the nail centrally into the distal fragment. Reduction must be maintained in order to prevent malalignment. Fractures with intraarticular extension should be stabilized first using either percutaneous screws or limited open fixation before nailing to prevent propagation or displacement (25).

As previously described for proximal tibial fractures several authors have advocated the use of Poller screws to obtain reduction and maintain alignment in distal tibia fractures. The screws can be inserted percutaneously to decrease the width of the distal medullary canal, facilitate reduction, and prevent nail translation. In fractures with preoperative varus or valgus angulation, an a.p. Poller screw may be placed along the proximal medial side and respectively lateral side of the distal fragment to direct central passage of the nail (27, 28).

These changes in operative technique help to reduce the incidence of primary malalignment in distal tibial fractures.

Maintaining a stable reduction to prevent secondary malalignment can also be difficult. Cases of angular malunion have been published by several authors (23, 28, 32, 34, 36). The new tibial nail design with interlocking holes in close proximity to the tip of the nail enables the placement of multiple screws in the distal fragment. Four distal interlocking holes within 37 mm from the nail tip are present in the ETN®. The use of four distal Locking Screws is sometimes necessary to get the optimal stabilization of a far distal fragment. However in most cases, three locking screws are sufficient.

For the treatment of metaphyseal tibial fractures with additional fibular fracture, Kumar et al. showed in a biomechanical cadaver model that fibular plate fixation reduced axial rotation and improved overall construct stability in distal tibia fibular fractures (29). Egol et al. confirmed these results in a retrospective clinical study. Results showed that supplementary fibular stabilization significantly enhanced the ability to maintain fracture reduction. The authors recommend fibular plating whenever intramedullary nailing is performed in unstable distal tibia-fibular fractures (11).

## ZÁVĚR

Při vývoji hřebu Expert tibial nail (tibiální hřeb pro experty) byla provedena řada modifikací tvaru hřebu i zajišťovacích šroubů. Tím bylo umožněno rozšířit indikaci pro hřebování tibie. Zajišťovací šrouby nyní umožňují optimální fixaci ve spongiózní kosti proximální metafýzy. Díky možnosti jejich zavedení v různých směrech je tak možné udržet jak správnou repozici, tak zajistit dostatečnou stabilitu osteosyntézy i u zlomenin s krátkým proximálním či distálním fragmentem. Čepička v proximální části hřebu navíc zajišťuje úhlovou stabilitu proximálního šikmo zavedeného zajišťovacího šroubu vůči hřebu. Změny ve tvaru implantátu zvýšily vzájemný kontakt hřebu s kostí a tím bylo sníženo riziko sekundární dislokace fragmentů. Hodnocení prospektivní série ošetřených případů přineslo výborné výsledky a rozšíření operačních indikací ve srovnání se standardními tibiálními hřebi.

## Literature

1. AHLERS, J., VON ISSENDORFF, W. D.: Incidence and causes of malalignment following tibial intramedullary nailing. *Unfallchirurgie*, 18: 31–36, 1992.
2. ALHO, A., EKELAND, A., STROMSOE, K., FOLLERAS, G., THORESEN, B. O.: Locked intramedullary nailing for displaced tibial shaft fractures. *J. Bone Jt Surg.*, 72-B: 805–809, 1990.
3. BHANDARI, M., GUYATT, G. H., SWIONTKOWSKI, M. F., SCHEMITSCH, E. H.: Treatment of open fractures of the shaft of the tibia. *J. Bone Jt Surg.*, 83-B: 62–68, 2001.
4. BHANDARI, M., GUYATT, G. H., SWIONTKOWSKI, M. F., TORNETTA, P., 3RD, HANSON, B., WEAVER, B., SPRAGUE, S., SCHEMITSCH, E. H.: Surgeons' preferences for the operative treatment of fractures of the tibial shaft. An international survey. *J. Bone Jt Surg.*, 83-A: 1746–1752, 2001.
5. BONE, L. B., SUCATO, D., STEGEMANN, P. M., ROHRBACHER, B. J.: Displaced isolated fractures of the tibial shaft treated with either a cast or intramedullary nailing. An outcome analysis of matched pairs of patients. *J. Bone Jt Surg.*, 79-A: 1336–1341, 1997.
6. BUEHLER, K. C., GREEN, J., WOLL, T. S., DUWELIUS, P. J.: A technique for intramedullary nailing of proximal third tibia fractures. *J. Orthop. Trauma*, 11:218–223, 1997.
7. COURT-BROWN, C. M., CHRISTIE, J., MCQUEEN, M. M.: Closed intramedullary tibial nailing. Its use in closed and type I open fractures. *J. Bone Jt Surg.*, 72-B: 605–611, 1990.
8. COURT-BROWN, C. M., WILL, E., CHRISTIE, J., MCQUEEN, M. M.: Reamed and unreamed nailing for closed tibial fractures. *J. Bone Jt Surg.*, 78-B: Br, 78: 580–583, 1996.
9. DOGRA, A. S., RUIZ, A. L., THOMPSON, N. S., NOLAN, P. C.: Dia-metaphyseal distal tibial fractures-treatment with a shortened intramedullary nail: a review of 15 cases. *Injury*, 31: 799–804, 2000.
10. DROSOS, G. I., BISHAY, M., KARNEZIS, I. A., ALEGAKIS, A. K.: Factors affecting fracture healing after intramedullary nailing of the tibial diaphysis for closed and grade I open fractures. *J. Bone Jt Surg.*, 88-B: 227–231, 2006.
11. EGOL, K. A., WEISZ, R., HIEBERT, R., TEJWANI, N. C., KOVAL, K. J., SANDERS, R. W.: Does fibular plating improve alignment after intramedullary nailing of distal metaphyseal tibia fractures? *J. Orthop. Trauma*, 20: 94–103, 2006.

12. FREEDMAN, E. L., JOHNSON, E. E.: Radiographic analysis of tibial fracture malalignment following intramedullary nailing. *Clin. Orthop. Relat. Res.*, 315: 25–33, 1995.
13. GAEBLER, C., STANZL-TSCHEGG, S., HEINZE, G., HOLPER, B., MILNE, T., BERGER, G., VECSEI, V.: Fatigue strength of locking screws and prototypes used in small diameter tibial nails: a biomechanical study. *J. Trauma*, 47: 379–384, 1999.
14. GEORGE, C. J., LINDSEY, R. W., NOBLE, P. C., ALEXANDER, J. W., KAMARIC, E.: Optimal location of a single distal interlocking screw in intramedullary nailing of distal third femoral shaft fractures. *J. Orthop. Trauma*, 12: 267–272, 1998.
15. GORCZYCA, J. T., MCKALE, J., PUGH, K., PIENKOWSKI, D.: Modified tibial nails for treating distal tibia fractures. *J. Orthop. Trauma*, 16: 18–22, 2002.
16. GREITBAUER, M., HEINTZ, T., GAEBLER, C., STOIK, W., VECSEI, V.: Unreamed nailing of tibial fractures with the solid tibial nail. *Clin. Orthop. Relat. Res.*, 350: 105–14, 1998.
17. HANSEN, M.: Proximal Tibial Nail (PTN) – Biomechanical Investigation. *Akt Traumatologie*, 35: 134–139, 2005.
18. HANSEN, M., GERCEK, E., BLUM, J., ROMMENS, P. M.: Osteosynthetische Versorgung proximaler extraartikulärer Tibiafrakturen – indikationen, Komplikationen, Ergebnisse. *Europ. J. Trauma*, 25: 174–182, 1999.
19. HANSEN, M., MEHLER, D., HESSMANN, M. H., BLUM, J., ROMMENS, P. M.: Biological risks and biomechanical advantages of triplanar proximal interlocked nailing in high tibial fractures. *J. Orthop. Trauma*, 18 (Suppl.): 50, 2004.
20. HANSEN, M., MEHLER, D., ROMMENS, P. M.: Das biomechanische Verhalten winkelstabiler Implantatsysteme an der proximalen Tibia. Edited, Bern, Hans Huber Verlag 2004.
21. HANSEN, M., MEHLER, D., VOLTMER, W., ROMMENS, P. M.: The extraarticular proximal tibial fractures. *Unfallchirurg*, 105: 858–872, 2002.
22. HENLEY, M. B., MEIER, M., TENCER, A. F.: Influences of some design parameters on the biomechanics of the unreamed tibial intramedullary nail. *J. Orthop. Trauma*, 7: 311–319, 1993.
23. IM, G. I., TAE, S. K.: Distal metaphyseal fractures of tibia: a prospective randomized trial of closed reduction and intramedullary nail versus open reduction and plate and screws fixation. *J. Trauma*, 59: 1219–1223, discussion 1223, 2005.
24. JONES, B. G., MEHIN, R., YOUNG, D.: Anatomical study of the placement of proximal oblique locking screws in intramedullary tibial nailing. *J. Bone Jt Surg.*, 89-B: 1495–1497, 2007.
25. KONRATH, G., MOED, B. R., WATSON, J. T., KANESHIRO, S., KARGES, D. E., CRAMER, K. E.: Intramedullary nailing of unstable diaphyseal fractures of the tibia with distal intraarticular involvement. *J. Orthop. Trauma*, 11: 200–205, 1997.
26. KRAG, M. H.: Biomechanics of the thoracolumbar spine fixation. *Spine*, 15: 311–317, 1991.
27. KRETTEK, C., MICLAU, T., SCHANDELMAIER, P., STEPHAN, C., MOHLMANN, U., TSCHERNE, H.: The mechanical effect of blocking screws ("Poller screws") in stabilizing tibia fractures with short proximal or distal fragments after insertion of small-diameter intramedullary nails. *J. Orthop. Trauma*, 13: 550–553, 1999.
28. KRETTEK, C., STEPHAN, C., SCHANDELMAIER, P., RICHTER, M., PAPE, H. C., MICLAU, T.: The use of Poller screws as blocking screws in stabilising tibial fractures treated with small diameter intramedullary nails. *J. Bone Jt Surg.*, 81-B: 963–968, 1999.
29. KUMAR, A., CHARLEBOIS, S. J., CAIN, E. L., SMITH, R. A., DANIELS, A. U., CRATES, J. M.: Effect of fibular plate fixation on rotational stability of simulated distal tibial fractures treated with intramedullary nailing. *J. Bone Jt Surg.*, 85-A: 604–608, 2003.
30. LAFLAMME, G. Y., HEIMLICH, D., STEPHEN, D., KREDER, H. J., WHYNE, C. M.: Proximal tibial fracture stability with intramedullary nail fixation using oblique interlocking screws. *J. Orthop. Trauma*, 17: 496–502, 2003.
31. LANG, G. J., COHEN, B. E., BOSSE, M. J., KELLAM, J. F.: Proximal third tibial shaft fractures. Should they be nailed? *Clin. Orthop. Relat. Res.*, 315: 64–74, 1995.
32. MOSHEIFF, R., SAFRAN, O., SEGAL, D., LIEBERGALL, M.: The unreamed tibial nail in the treatment of distal metaphyseal fractures. *Injury*, 30: 83–90, 1999.
33. MÜLLER, C.: Die Marknagelung der Tibia mit einem neuen Implantatsystem (TNS). In: *Klinik und Poliklinik für Unfallchirurgie*, pp. 100. Edited, 100, Mainz, Johannes Gutenberg Universität Mainz 2007.
34. NORK, S. E., SCHWARTZ, A. K., AGEL, J., HOLT, S. K., SCHRICK, J. L., WINQUIST, R. A.: Intramedullary nailing of distal metaphyseal tibial fractures. *J. Bone Jt Surg.*, 87-A: 1213–1221, 2005.
35. RICCI, W. M., O'BOYLE, M., BORRELLI, J., BELLABARBA, C., SANDERS, R.: Fractures of the proximal third of the tibial shaft treated with intramedullary nails and blocking screws. *J. Orthop. Trauma*, 15: 264–270, 2001.
36. ROBINSON, C. M., MCLAUCHLAN, G. J., MCLEAN, I. P., COURT-BROWN, C. M.: Distal metaphyseal fractures of the tibia with minimal involvement of the ankle. Classification and treatment by locked intramedullary nailing. *J. Bone Jt Surg.*, 77-B: 781–787, 1995.
37. ROTH, D. L. Edited, 240–258, American Society of Metals, 1992.
38. RUSSO, C. R., LAURETANI, F., SEEMAN, E., BARTALI, B., BANDINELLI, S., DI IORIO, A., GURALNIK, J., FERRUCI, L.: Structural adaptations to bone loss in aging men and women. *Bone*, 38: 112–118, 2006.
39. SCHMIDT, A. H., FINKEMEIER, C. G., TORNETTA, P., 3RD: Treatment of closed tibial fractures. *Instr. Course Lect.*, 52: 607–622, 2003.
40. STEINBERG, E. L., GELLER, D. S., YACOUBIAN, S. V., SHASHA, N., DEKEL, S., LORICH, D. G.: Intramedullary fixation of tibial shaft fractures using an expandable nail: early results of 54 acute tibial shaft fractures. *J. Orthop. Trauma*, 20: 303–309, discussion 315–316, 2006.
41. STRIEGEL, A.: Die Marknagelung der Tibia mit einem neuen Implantatsystem (Expert Tibia Nail). In: *Klinik und Poliklinik für Unfallchirurgie*. Edited, Mainz, Johannes Gutenberg Universität Mainz 2007.
42. TORNETTA, P., 3RD, COLLINS, E.: Semiextended position of intramedullary nailing of the proximal tibia. *Clin. Orthop. Relat. Res.*, 328: 185–189, 1996.
43. WHITTLE, A. P., WESTER, W., RUSSELL, T. A.: Fatigue failure in small diameter tibial nails. *Clin. Orthop. Relat. Res.*, 315: 119–128, 1995.

*Figures of the Expert Tibial Nail® and the operative technique were taken from the Synthes® Expert Tibial Nail® Surgical Technique Manual.*

Dr. Sebastian Kuhn,  
Department of Trauma Surgery  
University Hospital of the  
Johannes Gutenberg-University of Mainz,  
Langenbeckstr. 1,  
551 01 Mainz  
Germany  
Phone +49-6131-177292  
fax: +49-6131-176687  
E-mail: kuhn@unfall.klinik.uni-mainz.de

Práce byla přijata 20. 2. 2008.