

# Patellar Tendinopathy: Histopathological Examination and Follow-up of Surgical Treatment

## Entezopatie ligamentum patellae: histopatologické vyšetření a výsledky chirurgické léčby

M. PEĆINA, I. BOJANIĆ, A. IVKOVIĆ, L. BRČIĆ, T. SMOLJANOVIĆ, S. SEIWERTH

Department of Orthopaedic Surgery, University of Zagreb School of Medicine, University Hospital Center Zagreb, Croatia

### ABSTRACT

#### PURPOSE OF THE STUDY

The aim of this study was to determine the exact localization of the histopathological process (bone, bone-tendon junction or tendon), and to determine whether the underlying pathologic process is predominantly of inflammatory or degenerative nature, then to evaluate the outcome of the surgical treatment of patellar tendinopathy.

#### MATERIALS

A prospective cohort study was performed in order to analyze the outcome of surgical treatment of patellar tendinopathy, as well as to document histopathological changes in bone, bone-tendon junction, and in the patellar ligament in 34 professional athletes treated with patellar apicotomy. All the patients included in the study were classified as stage 3 according to Blazina and showed no improvement after at least 6 months of conservative treatment. The postoperative follow-up was from 1 to 8 years with a mean value of 4.7 years.

#### METHODS

The postoperative results were analyzed using a semiquantitative scoring system where the functional outcome was classified as very good if the athlete returned to his sporting activity without any negative side effects, good if the athlete resumed his sporting activities with modest painful sensations present only at the maximum level of physical exertion, and poor if any reduction of athletic activity was present.

In twenty patients a histopathological examination of resected bone and tendon tissue was performed. The specimens were stained with hematoxylin-eosin and examined under a light microscope using polarization. Special stains used were Alcian blue, to detect any increase in ground substance, and Prussian blue which enhances conspicuity of hyaline degeneration and enables detection of hemosiderin. Immunohistochemistry was performed in order to analyze presence of blood vessels, leukocytes and histiocytes.

#### RESULTS

Very good results were achieved in 20 of operated knees, good results were achieved in 12 of knees and poor results were achieved in 2 of operated knees. Pathological changes in the bone were found in 35% of analyzed specimens, abnormality at the bone-tendon junction were found in 75% of the specimens, and changes in the patellar tendon were found in all extracted specimens. The histopathological nature of the lesions found within the tendon tissue in all of the analyzed specimens belongs to the group of degenerative changes.

#### DISCUSSION

Currently a consensus has been established that the expression tendinitis is “out”, and the term tendinopathy should be used instead. No inflammatory cells and no increase in prostaglandins can be detected in the tendons. Histopathological studies of the tissue fibrils affected by tendinosis characteristically demonstrate hypercellularity, hypervascularity, lack of inflammatory infiltrates, and disorganization and loosening of collagen fibers.

#### CONCLUSION

The clinical results and histopathological examination in our series justified our operative method. In the chronic stage these lesions are irreversible and constitute permanent intratendinous lesions. It thus seems logical to excise these lesions from their origin at the apex of the patella and entry into the adjacent tendon. It is also recommended on the basis of our and other authors' research that the term patellar tendinopathy should be used instead of tendonitis/tendinitis.

**Key words:** knee, patellar tendon, tendinitis, tendinopathy, athletes.

**INTRODUCTION**

Patellar tendinopathy is a common overuse syndrome frequently encountered in athletes engaged in activities that place strong and repetitive mechanical strain on the knee extensor system, and is thus most prevalent in sports involving jumping, landing, as well as rapid acceleration and deceleration (6). Other terms that apply to the same syndrome are also present in the medical literature: patellar tendinopathy, patellar or quadriceps tendonitis, patellar apicitis, enthesitis apices patellae, jumper's knee, volleyball's knee, basketball's knee. Volleyball, basketball, handball, soccer players and dancers have significantly higher risk of developing this condition (7, 18, 21).

The clinical picture of patellar tendinopathy is characterized by the presence of pain on the apex of the patella as the major symptom, and a decreased functional ability of the afflicted lower extremity. The diagnosis is usually made based on intensity of the pain and the exact time of pain onset with respect to the duration of physical activity (before, during or after the beginning of the activity). The diagnostic process is usually supplemented by imaging methods such as magnetic resonance (MR) and ultrasound (14, 20, 22, 30). A staging system has been developed based on the clinical symptoms (5).

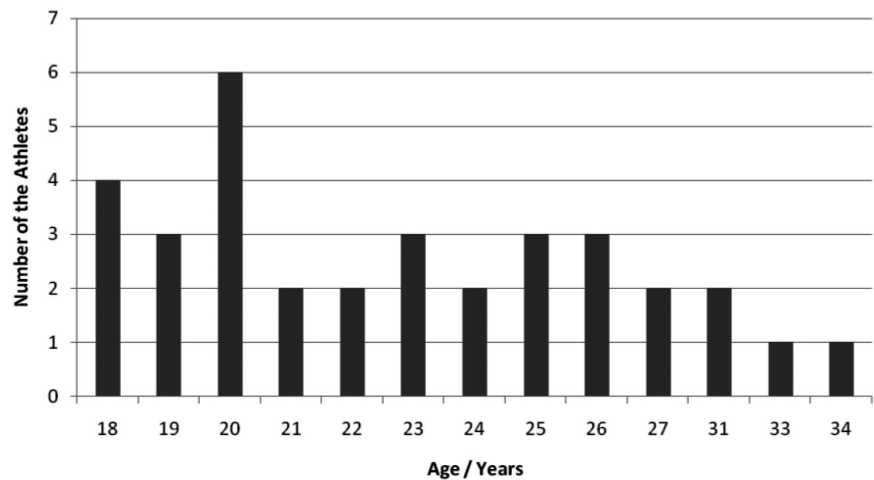
high-level professional athletes, as well as to elucidate the histopathological changes within the affected tendons.

**MATERIAL AND METHODS**

We present a prospective series of 34 professional athletes (26 males and 8 females) seen and treated from 1989 to 1997 for patellar tendinopathy. All the patients elicited sharp pain in the area of the lower patellar pole that was reproduced on clinical examination with palpation and extension of the lower leg against resistance. All the patients described pain during and after activity with increasing difficulty in performing at a satisfactory level and were classified as stage 3 according to Blazina (5). Ultrasound findings were consistent with clinical stage of patellar tendinopathy.

All patients failed to show any improvement after at least 6 months of a well-supervised nonoperative program consisting of relative rest and physical therapy followed by stretching and strengthening exercises of the upper leg muscles. Of 34 professional athletes in our study group 11 played basketball, 5 soccer, 4 handball, 3 volleyball, 4 participated in track and field, 2 in rhythmic gymnastics, 2 in ballet, 2 in dance and 1 in ice hockey. Distribution of patients by age is showed in Figure

Figure 1. Distribution of operated athletes based on their age.



The treatment algorithm always starts with nonoperative methods consisting of rest and physical therapy followed by stretching and strengthening exercises of the upper leg muscles, especially by eccentric muscle training as introduced in recent years (3, 24). Surgical treatment is indicated only if a prolonged and well-supervised conservative treatment program fails (3, 6, 10, 21). It has been estimated that only about 10% of all patients with patellar tendinopathy undergo operative treatment (21). There is no clear consensus in the literature on the best surgical procedure for patellar tendinopathy when nonoperative treatment fails.

The aim of this paper is to report on long-term results after the surgical treatment of patellar tendinopathy in

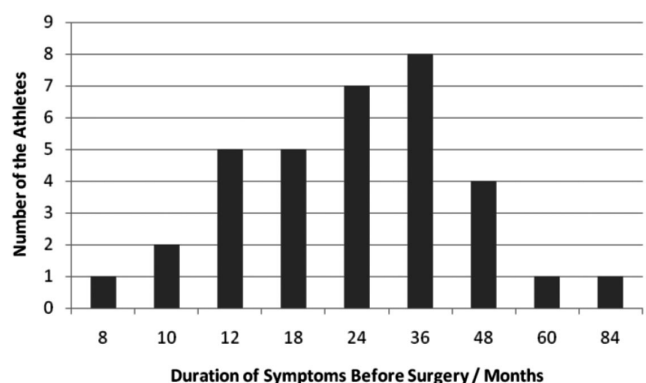


Figure 2. Distribution of athletes based on the duration of symptoms before the surgery.

1 and duration of symptoms prior to surgery ranged from 8 to 84 months (Figure 2).

Patients were operated under spinal anesthesia, lying supine with the leg placed in the holder and knee flexed to 90°. A thigh tourniquet was inflated just before the incision to provide hemostasis. Knee arthroscopy was performed to resolve any concomitant intra-articular injury. A straight, 3-cm midline incision was made to expose the proximal part of the patellar tendon. The paratenon was incised in line with the skin and carefully dissected. An open apicotomy or a trapezoidal bony fragment was removed from the tip of the patella similarly to the Kenneth-Jones procedure of taking a loose transplant for the reconstruction of the anterior cruciate ligament (10). Thickened, degenerated tissue was usually found in the mid-dorsal part of the tendon and was carefully dissected as shown in Figure 3. The excision finishes approximately 3 cm below the lower patellar pole. The tendon and paratenon were not repaired, the subcutaneous tissue was approximated with fine absorbable sutures, and the skin was closed with interrupted nylon sutures. Intra-articular suction drainage was left for 24 hours. An immediate motion exercises was started on the second postoperative day under the guidance of a physical therapist. Quadriceps strengthening exercises were introduced as soon as patients could tolerate them. Light training was allowed on the 6<sup>th</sup> postoperative week if full active and passive motion was restored. The load on the patellar tendon was gradually increased and unrestricted training was allowed 3 months after surgery. Return to competitive sports was scheduled 4 months after the surgery. Patients were reviewed in our outpatient clinic for an average of 4.7 years (range 1 to 8 years). The postoperative results were classified as very good if the athlete returned to his sport activity without any negative side effects, good if the athlete resumed his sports activities with painful sensations present only at the maximum level of physical exertion, and poor if any reduction of athletic activity was present.

In 20 surgically treated patients histopathological examination of resected bone and tendon tissue was performed. Tissue samples were fixed in 4% buffered formaldehyde, followed by decalcification for bone fragments, and embedded in paraffin. The specimens were stained with hematoxylin-eosin and examined under a light microscope using polarization. Special stains used were Alcian blue, to detect any increase in ground substance, and Prussian blue which enhances conspicuity of hyaline degeneration and enables detection of hemosiderin. In order to analyze blood vessels, leukocytes and histiocytes, immunohistochemistry was performed. For blood vessel identification we used CD31, LCA for leukocytes, and CD68 antibodies for histiocytes (all antibodies by Dako, Glostrup, Denmark). Analysis was performed semi quantitatively using the following scale for blood vessels: 1: 1 to 3 vascular spaces per high power visual field (HPF), 2: 4 to 10 vascular spaces per HPF 3: more than 10 vascular spaces per HPF. Assessment of inflammatory cells was done using the following scale: 1: single cells positive for CD68 or

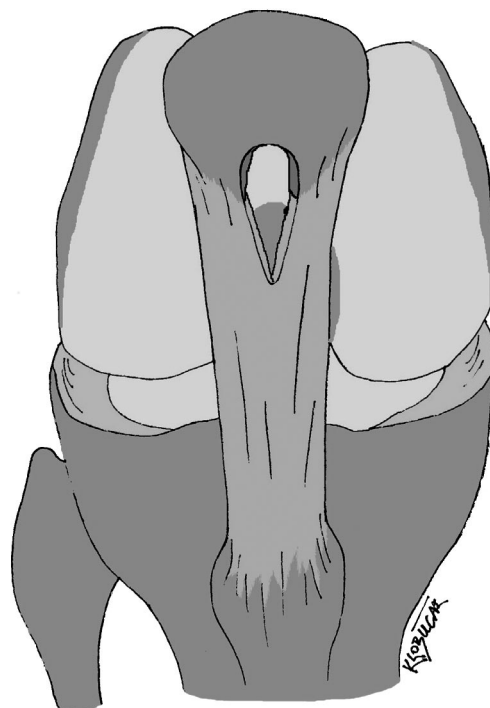


Figure 3. Half-open arthroscopically assisted surgical procedure of patellar apicotomy and partial excision of degeneratively changed tendon.

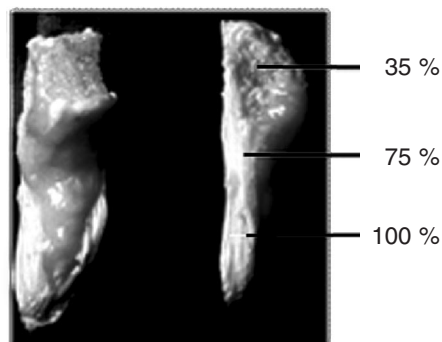


Figure 4. Localization of the pathological process at apical part of patella, bone-tendon junction, and patellar tendon.

LCA antibodies, 2: small groups of positive cells and 3: big groups or many smaller groups of positive cells. All above mentioned reactivity was analysed in the two high-power fields with the highest immunoreactivity (hot-spot assessment).

## RESULTS

The group was composed of 26 men and 8 women with ages ranging from 18 to 34, with a mean age of 23 years at the time of the procedure. Of 34 professional athletes in our study group none of them reported knee trauma prior to the onset of symptoms. Overall, on the basis of the evaluation scale previously described 20 patients achieved very good result, 12 patients had good

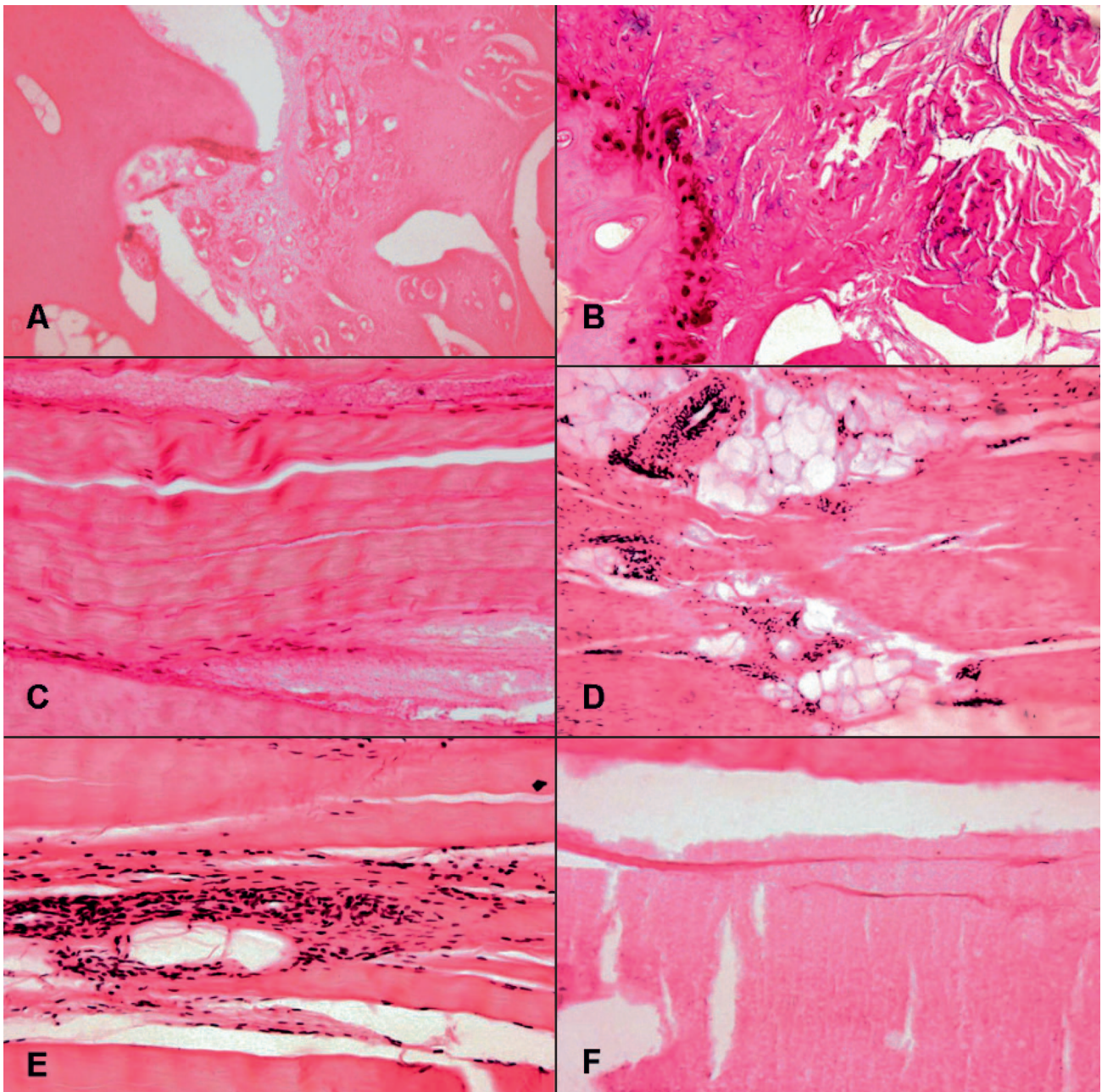


Figure 5. Pathological changes in bone, bone-tendon junction and tendon (A); replacement of bone marrow by highly vascularized granulation tissue (B); fibrocartilaginous metaplasia and mucoïd degeneration in bone-tendon junction (C); loss of tenocytes and microtears in tendon (D); tendon infiltrated with fat tissue (E); increased number of small blood vessels (F); complete degeneration of tendon.

result, whereas 2 patients had poor result. All the patients with very good and good result resumed athletic activity within 6 months postoperatively.

Pathological changes in the extracted specimens (Figure 4) were found in the bone in 35 % of analyzed specimens and included: foci of necrosis, fatty changes in cancelous bone, bone marrow which was replaced by highly vascularized granulation tissue with scattered mononuclear inflammatory cells. Abnormalities in the bone-tendon junction were found in 75% of the specimens and included: microtears of the tendinous tissues,

destruction of bony architecture, foci of ossification, chronic inflammatory cell infiltration, exaggerated fibrocartilaginous metaplasia and mucoïd degeneration. Changes in the patellar tendon were found in all specimens and included: cellular proliferation within the tendinous tissue accompanied by a prominence of capillary proliferation, chronic inflammatory cell infiltration, hyaline degeneration, mucoïd degeneration, microtears of the tendinous tissues, neovascularization and tenocyte infiltration (Figure 5). Immunohistochemical analysis of the number of vascular spaces demonstrated inc-

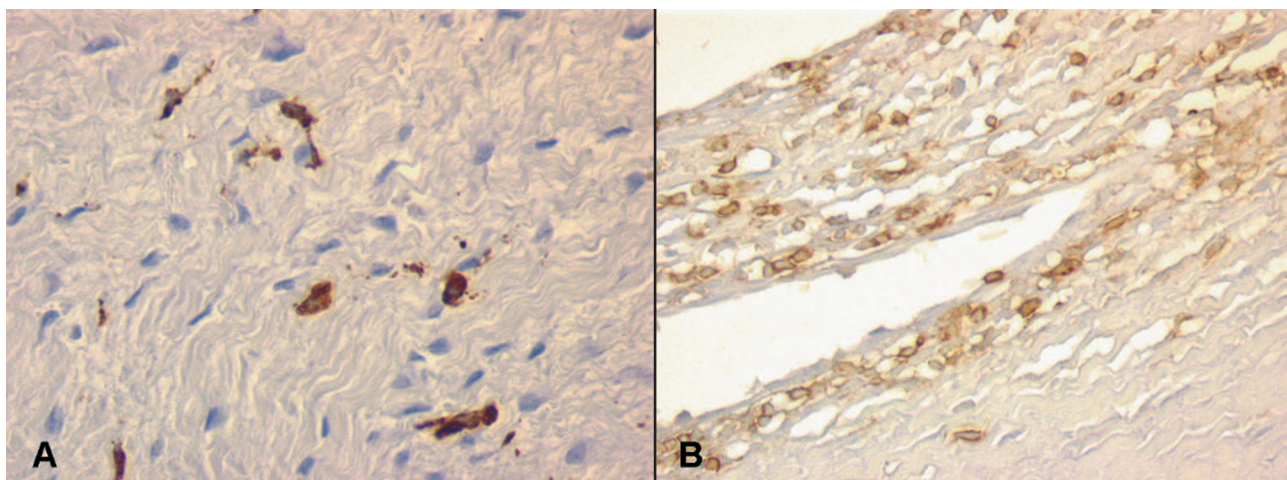


Figure 6. Immunohistochemical presentation of CD 68 and LCA positive cells in tendon. Single cells and small groups of cells positive for CD 68 antibody (A) indicating histiocytes, and LCA positive cells (B) demonstrating leukocytes.

reased number in all but two samples. In the same two samples there were practically no leukocytes present, while in all other samples single positive cells or small groups of leukocytes and small groups of histiocytes were present (Figure 6). Polarization microscopy showed loss of clear demarcation of collagen bundles accompanied by a loss of the normal dense, homogeneous polarization pattern.

## DISCUSSION

The detailed description of the clinical picture and a management algorithm were originally published by Blazina (5), who, at the same time, also introduced the term *jumper's knee* to the medical literature. Although commonly used among practitioners this term is somewhat misleading because this injury can be found in various athletes, not only in those participating in jumping activities. Similar "confusion" has also arisen when it came to the nature of the pathophysiological process within the tendon tissue that underlies the clinical symptoms. For a long time the term patellar tendinitis was used, and it implied that inflammatory changes predominate. However, intensive research in the past decade within the field has brought numerous changes to our understanding of the underlying pathophysiological process, and basic science research suggest little or no inflammation present in tendons exposed to overuse. Histopathological changes documented in our study are consistent with reports from other authors, and the predominant lesion is one of degenerative change (16). Macroscopic changes include loss of normal tendon color which turns grey or brown instead of being brilliant white, and a loss of firm and fibroelastic texture of the tissue which becomes soft, thin and fragile. Microscopic changes include degeneration and disorganization of collagen fibers, increased cellularity and minimal inflammation. The hypercellularity observed in patellar tendinopathy is caused by increased cell proliferation associated with increased expression of platelet-derived

growth factor receptor -beta (PDGFR-beta) (25). Additionally, neovascularization is consistently identified in histological specimens and during powered Doppler ultrasound examination, as well as ingrowths of small nerves (12).

Numerous signaling pathways and cellular mechanisms that lead to tendinopathy have been recently elucidated, and we are only beginning to master methodologies to evaluate tissue changes in tendons exposed to repetitive mechanical loading during sporting activities (17). Several changes occur in tendons in response to high-strain cycling loading including cell apoptosis, increased production of matrix metalloproteinases (MMPs), chondroid metaplasia of the tendon, as well as upregulation of certain factors and enzymes such as insulin-like growth factor-1 (IGF-1) and nitric oxide synthase (NOS) (11). Most of these cellular and molecular events are pathological, but some of them exert protective effect and appear to be beneficial. It seems that overall pathological changes are consistent with impaired balance between noxious repetitive stimulus and a failed attempt to regenerate damaged tendon tissue. The net result is tendon degeneration, followed by a clinical picture of patellar tendinopathy. Another important feature is the increased amount of apoptosis in a degenerative tendon. It has been demonstrated that cyclic strain was associated with an activation of stress-activated protein kinases (SAPK-s) in several cultured cell lines (2). These SAPK-s, in turn, were shown to be important upstream regulators of a variety of cell processes including apoptosis. Other stress-related genes such as flice inhibitory protein (FLIP), heat shock-related protein 27 (HSP27) and testis heat shock-related protein 70 (HST70) have been identified in animal models of cyclical strain. Bi Y. et al (4) identified a cell population termed tendon stem/progenitor cells (TSPCs) with universal stem cell features such as self-renewal capacity, clonogenicity and multipotency (especially towards chondrogenesis). It has been suggested that the terminal differentiation of these cells might be influenced by envi-

ronmental factors and signals. The current hypothesis that conceptually summarizes all these new data proposes that high doses of repetitive strain induce genes for two major pathways: oxidative stress-apoptosis and cartilage-like genes, producing all of the mentioned histopathological, cellular and molecular events, resulting in the clinical picture of patellar tendinopathy (29).

Although most clinicians presently agree that tendinopathy is an overuse phenomenon, there are still many debates over the most efficient treatment protocol. Most protocols start with activity modification and eccentric strengthening programs. Transcutaneous application of glyceryl trinitrate (GTN) patches and extracorporeal shockwave therapy (ESWT) seem to be safe and promising treatments for patellar tendinopathy with a positive effect on pain and function, but larger prospective trials validating the true efficacy of these modalities are needed (28). Alfredsson and Ohlberg (1) stressed the significance of neovascularization in chronic painful patellar tendinopathy and suggested that ablation of small blood vessels in areas of tendinopathy leads to eradication of pain-generating nerve fibers. A recently published double-blind, controlled, and randomized study, comparing polidocanol (a sclerosing agent) and lidocain injections for the treatment of patellar tendinopathy, showed improvement in the treatment group when compared to the control group (14). Although promising, these results need more validation by other investigators in controlled, multicenter clinical trials. The clinical results of the efficacy of multiple platelet-rich plasma (PRP) injections are encouraging, indicating that PRP injections have the potential to promote the achievement of a satisfactory clinical outcome, even in difficult cases with chronic refractory tendinopathy where previous treatment modalities have failed. Frei, R. et al. (9) analyzed one of the new therapeutic approaches—the use of autologous growth factors in orthopaedics and traumatology. Growth factors, such as platelet-derived growth factor, transforming growth factors and others, exert effects on fibroplastic events during ontogenesis as well as on regeneration of injured tissues.

Surgical treatment has been recommended when non-operative treatment fails. This is particularly true in the case of elite athletes where prolonged absence from training and competition may be detrimental for their carriers. Open tenotomy and debridement used in this study proved to be a safe and effective technique with 59% of results being excellent and 35% of results being good. It seems to be a reliable option for elite athletes with very high functional demands and, in combination with a well-structured postoperative rehabilitation protocol, produces satisfactory results. Most of the investigators agree that the open procedure is still the golden standard, but other techniques such as drilling of the inferior patellar pole, ultra-sound guided percutaneous longitudinal tenotomy and arthroscopic patellar tenotomy have been successfully used in the treatment of patellar tendinopathy (19, 26). During the arthroscopical procedure it is necessary, also, pay attention to eventually existing medial patellar plica of the knee (15).

The main weakness of this study is the fact that it lacks a control group and randomization. Due to the fact that all of the patients were prominent athletes, our decision was to perform the best possible treatment in all cases. This decision prevented the use of more appropriate research methodology and introducing a control group. However, we feel that this study will contribute to the better understanding of underlying pathology and possible treatment options in athletes with patellar tendinopathy.

## CONCLUSION

The clinical results and histopathological examination in our series justified our operative method. In the chronic stage these lesions are irreversible and constitute permanent intratendinous lesions. It thus seems logical to excise these lesions from their origin at the apex of the patella and entry into the adjacent tendon. Our histopathological analysis confirmed the degenerative nature of the process within the tendon, and the correct term for this overuse injury is patellar tendinopathy. Based on data obtained from basic science research, many new treatment modalities have emerged. These include TGN patches, ESWT, sclerotherapy and PRP injections, stem cell therapy, growth factor treatment, and gene transfer. Although many of these modalities are still experimental, they could potentially reverse the degenerative process and promote regeneration of and healing of the affected tendon.

## References

1. ALFREDSON, H., OHLBERG, L.: Neovascularisation in chronic painful patellar tendinosis – promising results after sclerosing neovessels outside the tendon challenge need for surgery. *Knee Surg. Sports Traumatol. Arthrosc.*, 13: 74–80, 2005.
2. ARNOČEKY, S. P., TIAN, T., LAVAGNINO, M., GARDNER, K., SCHULER, P., MORSE, P.: Activation of stress-activated protein kinases (SAPK) in tendon cells following cyclic strain: the effects of strain frequency, strain magnitude, and cytosolic calcium. *J. Orthop. Res.*, 20: 947–952, 2002.
3. BAHR, R., FOSSAN, B., LOKEN, S., ENGBRETTSEN, L.: Surgical treatment compared with eccentric training for patellar tendinopathy (Jumper's Knee). A randomized, controlled trial. *J. Bone Jt Surg.*, 88-A: 1689–1698, 2006.
4. BI, Y., EHIRCHIOU, D., KILTS, T. M., INKSON, C. A., EMBREE, M. C., SONOYAMA, W., LI, L., LEET, A. I., SEO, B. M., ZHANG, L., SHI, S., YOUNG, M. F.: Identification of tendon stem/progenitor cells and the role of the extracellular matrix in their niche. *Nat. Med.*, 13: 1219–1227, 2007.
5. BLAZINA, M. E., KERLAN, R. K., JOBE, F. W., KARTER, V. S., CARLSON, G. J. Jumper's knee. *Orthop. Clin. N. Amer.*, 4: 665–678, 1973.
6. COOK, J.L., KHAN, K.M., HARCOURT, P.R., GRANT, M., YOUNG, D.A., BONAR, S.F.: A cross sectional study of 100 athletes with jumper's knee managed conservatively and surgically. *Brit. J. Sports Med.*, 31: 332–336, 1997.
7. FERRETTI, A.: Epidemiology of jumper's knee. *Sports Med.*, 3: 289–295, 1986.
8. FILARDO, G., KON, E., DELLA VILLA, S., VINCENTELLI, F., FORNASARI, P.M., MARCACCI, M.: Use of platelet-rich plasma for the treatment of refractory jumper's knee. *Int. Orthop.*, DOI: 10.1007/s00264-009-0845-7, 2009.

9. FREI, R., BIOSCA, F. E., HANDL, M., TRČ, T.: The Role of Growth Factors in the Human Organism and Their Use in Medicine, Especially in Orthopaedics and Traumatology. *Acta Chir. orthop. Traum. čech.*, 75: 247–252, 2008.
10. FRITCHY, D., WALLENSTEN, R.: Surgical treatment of the patellar tendonitis. *Knee Surg. Sports Traumatol. Arthrosc.*, 1: 131–133, 1993.
11. FU, S. C., Chan, K. M., ROLF, C. G.: Increased deposition of sulphated glycosaminoglycans in human patellar tendinopathy. *Clin. J. Sport Med.*, 17: 129–134, 2007.
12. GISSLEN K., ALFREDSON, H.: Neovascularisation and pain in jumper's knee: a prospective clinical and sonographic study in elite junior volleyball players. *Brit. J. Sports Med.*, 39: 423–428, 2005.
13. HAMILTON, B., PURDAM, C.: Patellar tendinosis as an adaptive process: a new hypothesis. *Brit. J. Sports Med.*, 38: 758–761, 2004.
14. HOKSRUD, A., OHBERG, L., ALFREDSON, H., BAHR, R.: Ultrasound-guided sclerosis of neovessels in painful chronic patellar tendinopathy: a randomized controlled trial. *Amer. J. Sports Med.*, 34: 1738–1746, 2006.
15. JEMELIK, P., STROVER, A.E., EVANS, G.: Results of Resection of Medial Patellar Plica through a Supero-lateral Portal as a Main Arthroscopic Procedure. *Acta Chir. orthop. Traum. čech.*, 75: 369–374, 2008.
16. KHAN, K.M., COOK, J.L., BONAR, F., HARCOURT, P., ASTROM, M.: Histopathology of common tendinopathies. Update and implications for clinical management. *Sports Med.*, 27: 393–408, 1999.
17. KJAER, M., LANGBERG, H., HEINEMEIER, K., BAYER, M. L., HANSEN, M., HOLM, L., DOESSING, S., KOMGSGAARD, M. R., MAGNUSSON, S. P.: From mechanical loading to collagen synthesis, structural changes and function in human tendon. *Scand. J. Med. Sci. Sports*, 19: 500–510, 2009.
18. KUJALA, M. H., KVIST, M., OSTERMAN, K.: Knee injuries in athletes, review of exertion injuries and retrospective study of outpatient sports clinic material. *Sports Med.*, 3: 447–460, 1986.
19. LORBACH, O., DIAMANTOPOULOS, A., PAESSLER, H. H.: Arthroscopic resection of the lower patellar pole in patients with chronic patellar tendinosis. *Arthroscopy*, 24: 167–173, 2008.
20. O'KEEFFE, S. A., HOGAN, B. A., EUSTACE, S. J., KAVANAGH, E. C.: Overuse injuries of the knee. *Magn. Reson. Imaging Clin. N. Amer.*, 17: 725–739, 2009.
21. PEČINA, M., BOJANIĆ, I.: *Overuse Injuries of the Musculoskeletal System*. 2nd Edition, Boca Raton, London, New York, Washington, D.C., CRC Press 2003.
22. PEERS, K. H., LYSSENS, R. J.: Patellar tendinopathy in athletes: current diagnostic and therapeutic recommendations. *Sports Med.*, 35: 71–87, 2005.
23. POPP, J. E., YU, J. S., KAEDING, C. C.: Recalcitrant patellar tendinitis. Magnetic resonance imaging, histological evaluation, and surgical treatment. *Amer. J. Sports Med.*, 25: 218–222, 1997.
24. REES, J. D., WOLMAN, R. L., WILSON, A.: Eccentric exercises why do they work, what are the problems and how can we improve them? *Brit. J. Sports Med.*, 43: 242–246, 2009.
25. ROLF, C. G., FU, B. S., PAUL, A., WANG, W., CHAN, B.: Increased cell proliferation and associated expression of PDGFRbeta causing hypercellularity in patellar tendinosis. *Rheumatology (Oxford)*, 40: 256–261, 2001.
26. ROMEO, A. A., LARSON, R. V.: Arthroscopic treatment of infrapatellar tendonitis. *Arthroscopy*, 15: 341–345, 1999.
27. SAMIRIC, T., PARKINSON, J., ILIC, M. Z., FELLER, J. A., HANDLEY, C. J.: Changes in the composition of the extracellular matrix in patellar tendinopathy. *Matrix Biol.*, 28: 230–236, 2009.
28. VAN LEEUWEN, M. T., ZWERVER, J., VAN DEN AKKERSCHEEK, I.: Extracorporeal shockwave therapy for patellar tendinopathy: a review of the literature. *Brit. J. Sports Med.*, 43: 163–168, 2009.
29. XU, Y., MURREL G. A.: The basic science of tendinopathy. *Clin. Orthop. Relat. Res.*, 466: 1528–1538, 2008.
30. WARDEN, S. J., KISS, Z. S., MALARA, F. A., OOI, A. B., COOK, J. L., CROSSLEY, K. M.: Comparative accuracy of magnetic resonance imaging and ultrasonography in confirming clinically diagnosed patellar tendinopathy. *Amer. J. Sports Med.*, 35: 427–436, 2007.

Prof. Marko Pečina, M.D., Ph.D.,  
Tel/fax: +385 (1) 455 0744,  
E-mail: marko.pecina@zg.t-com.hr