

Both Column Fractures of the Acetabulum: Epidemiology, Operative Management and Long-Term-Results

Zlomeniny obou pilířů acetabula. Epidemiologie, operační léčení a dlouhodobé výsledky

A. GÄNSSLEN¹, M. FRINK², F. HILDEBRAND², C. KRETTEK²

¹ Klinik für Unfallchirurgie, Orthopädie und Handchirurgie, Klinikum der Stadt Wolfsburg, Wolfsburg, Germany

² Unfallchirurgische Klinik, Medizinische Hochschule Hannover, Hannover, Germany

ABSTRACT

PURPOSE OF THE STUDY

Both column fractures, defined as an acetabular fracture with no articular fragment in connection with the axial skeleton account for approximately 20% of all acetabular fractures. The typical type of a both column acetabular fracture is the C1.2 fracture with a multifragmentary anterior column fracture extending to the iliac crest and a large posterior column fragment in more than half of the patients.

MATERIAL AND METHODS

The analysis of 135 surgically treated patients with both column fractures showed that more than half of these patients had associated injuries. The mean age was 40 years, and two thirds of these patients were male. A high energy trauma was the trauma mechanism in 87.4%. The mean ISS was 14.2 points.

The mean articular fracture displacement was 14.8 mm. 65.9% of the patients showed a central femoral head dislocation. An associated posterior wall fracture was present in 34.8% and an acetabular roof comminution in 34.1%. 8.9% of patients had a fracture related nerve damage.

RESULTS

Osteosynthesis was performed 9.6 days after trauma. Several approaches were used for stabilization with a combination of plate and screw fixation in 71.9%. The mean operative time was 287 minutes with a blood loss of 1796 ml. Postoperatively the hip joint was congruent in 94.7% with anatomical or near-anatomical joint reconstruction in 75.6%. Iatrogenic nerve injury occurred in 12 patients (8.9%).

89 patients (66.4%) could be followed after a mean of 54.6 months. The average subjective Visual Analog Scale pain score was 27.6. Mild or no pain was seen in 60.7%. The mean Merle d'Aubigné score was 15 with 60.7% of patients having a functionally perfect or good result. 61.8% had no post-traumatic osteoarthritic changes of their hip joint. A joint failure was diagnosed in 25.8% of the patients.

DISCUSSION

Analysing only patients with anatomically reconstructed hip joints patients had better results with 69.8% having no or mild pain and a good or excellent functional result. Post-traumatic arthrotic changes occurred in only 17.5% of these patients. A joint failure was present in 25.4%. In this group, a joint failure was significantly more likely to be present with an additional lesion of the femoral head and severe primary articular fracture displacement.

CONCLUSIONS

In contrast to other acetabular fracture types, both column fractures show worse results regarding joint reconstruction, and functional and radiological long-term results. The optimal results can be achieved with anatomic joint reconstruction.

Key words: acetabulum, both column fractures, osteosynthesis.

INTRODUCTION

Both column fractures of the acetabulum are a relatively common fracture type that is observed in about one fifth of cases in large cohorts (9, 22). A both column fracture is defined as an acetabular fracture where no articular fragment is in connection with the axial skeleton (11) (Fig. 1).

In the majority of previously published data on acetabular fractures patient groups, all fracture types are included and the summarizing the rates of good and excellent functional results are between 70 and 80% (in: (9)). Results of individual fracture types are rare and hardly related almost exclusively to posterior wall fractures (1, 19, 23).

No exact studies exist for both column fractures. Only general data on treatment strategy and some results can be found in the literature (11, 13, 17, 22, 26).

Therefore, it is of interest to further investigate epidemiological aspects and long-term results in this specific fracture type.

MATERIAL AND METHODS

Between 01.01.1972 and 31.12.2008 a total of 1208 patients (age at least 18 years) were treated with acetabular fractures at our institution. 239 of these had a both column fracture (incidence: 19.8%).

In 206 survivors (mortality rate: 13.8%), open reduction and internal fixation (ORIF) was performed in 135 (ORIF rate: 65.5%). These 135 patients were analyzed regrading demographical data (patient age, sex), type of accident, injury mechanism, type of admission, polytrauma rate (25) and ISS (2), concomitant pelvic ring injuries by AO/OTA classification (21), associated injuries and type of radiological diagnostics.

Traumatic brain injury (TBI) was graded according to the Glasgow Coma Scale (GCS) (24). Accompanying chest and abdominal injuries were classified according to the Organ Injury Scaling (OIS) (20). Additional pelvic ring injuries were analyzed alone and according to

the complex pelvic trauma definition (3). A fracture-related nerve damage was divided into primary and secondary (iatrogenic) nerve damage.

The primary fracture displacement, additional hip dislocation, acetabular roof arc measurement (14), time of surgical stabilization, surgical approach, and surgery time with blood loss as well as damage to the femoral head (contusion, impaction), the acetabulum (contusion, impaction, comminution zones) and the presence of an associated fracture of the posterior wall or intra-articular fragments were recorded.

The postoperative radiological result was graded according to Matta (15).

The follow-up was recorded using a standardized documentation form (22) including pain analysis and neurological impairments (7). The long-term functional outcome was classified according to the Merle d'Aubigné-score (18). Assessment of the radiological result included follow-up x-ray examination for post-traumatic osteoarthritis changes according to (in: (22)), the presence of femoral head necrosis according to Ficat and Arlet (8) and the presence of heterotopic ossification according to Brooker (4). In addition, the implantation of a secondary total hip prosthesis was documented.

A radiological joint failure was defined as the presence of post-traumatic osteoarthritis grade 4 and/or the presence of post-traumatic femoral head necrosis grade 3 or 4 and/or the presence of heterotopic ossification of grade 4 and/or secondary implantation of a total hip prosthesis.

RESULTS

Demographic data

There were 92 male and 43 female patients (68.1 vs. 31.9%). The average age was 40.2 ± 16.1 years (18-89 years).

The cause of the accident was a high energy trauma in 87.4% and a simple fall from standing or walking in 12.6%. 61.5% of patients were injured in road traffic accidents. In the majority of patients a direct collision (91.9%) was the main injury mechanism with a lateral force to the pelvis in 71.9%. Most patients (80.7%) were transferred to our hospital. 43% of the patients had an isolated pelvic trauma. 43.7% had multiple injuries and 13.3% were polytraumatized. The mean ISS was 14.2 ± 8.8 points (9-57 points).

Concomitant injuries

A total of 77 patients (57%) had associated injuries. An additional TBI was present in 25.9% of patients: 29x mild, 4x moderate 2x severe.

A chest trauma was present in 25.2% of cases (17x OIS I+II, 11x

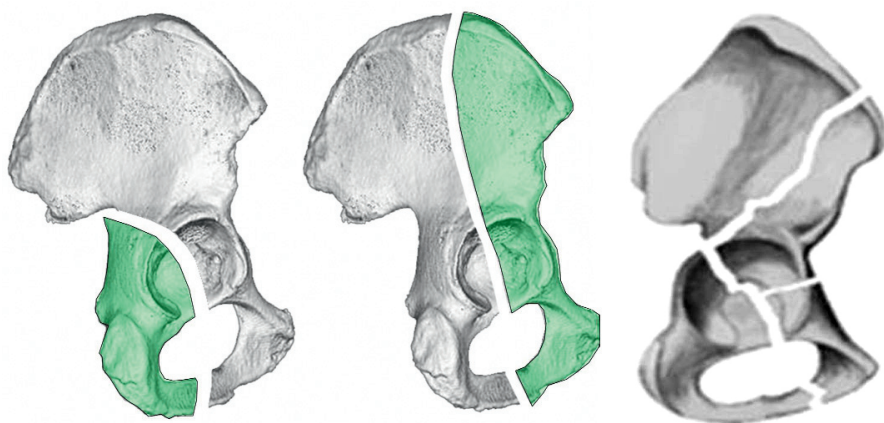


Fig. 1. Schematic view of a typical both-column fracture with a multifragmentary anterior column fracture starting high at the iliac crest and a simple fracture of the posterior column.

OIS III, 6x OIS IV+V). 15 patients (11.1%) suffered from blunt abdominal trauma. Splenic and liver injuries occurred in six patients. 22 patients (16.3%) sustained fractures of the upper and 23 patients (17%) fractures of the lower extremities.

A complex pelvic trauma was seen in seven patients (5.2%) (5x bladder ruptures, 1x urethral injury, 1x laceration of the common iliac vein).

A pelvic ring injury was present in 40 patients (29.6%). In 11.1% a contralateral type A2-injury and in eight patients a type B1-injury was present. Six of the latter had plate osteosynthesis of the symphysis. 10 patients (7.4%) had anterior sacral compression fractures (type B2) without need of surgical treatment.

In seven patients (5.2%) the both column fracture was associated with a pelvic ring type C-injury which was stabilized in four.

Radiological diagnostics

Radiological diagnostics included a standard anterior-posterior pelvic radiograph in all cases. Additional oblique views (ala and obturator oblique views) were performed in 77 patients (57%). A CT-scan of the pelvis was performed in 110 patients (81.5%).

Fracture characteristics

The typical type of a both column acetabular fracture is the C1.2 fracture according to the AO/OTA classification (51.9%). This fracture starts typically high at the iliac crest and shows a multifragmentary fracture of the anterior column with a simple fracture of the posterior column. Other types of fractures included five-C1.1 fractures, 28 C1.3 fractures, 13 C2.2 fractures, nine C2.3 fractures and 10 fractures involving the SI joint (C3).

The mean articular fracture displacement was $14.8 \text{ mm} \pm 7.8 \text{ mm}$ (2-43 mm). 65.9% of the patients showed a medialization of the femoral head (central dislocation) and in 2.2% a dorso-cranial hip joint dislocation. An associated fracture of the posterior wall was found in 47 patients (34.8%), whereas Pipkin fractures were not seen.

Reduction of the femoral head was performed immediately in 24 patients after 7.7 hours (0-37 hours) by closed reduction or traction treatment.

The mean anterior-posterior roof arc was 13.2° , on the iliac oblique view of 13.2° and 11.8° on the obturator-oblique view. A comminution zone of the acetabular roof was seen in 34.1% of the patients.

Perioperative data

Osteosynthesis was performed by a total of 28 different surgeons on average 9.6 ± 6.3 days after trauma (2-37 days).

Approaches used were an extended approach in 39 cases, a combined dorso-ventral approach in 36 cases, the ilioinguinal approach in 31 cases and the Kocher-Langenbeck approach in 18 cases. In four cases a Smith-Peterson-approach and in seven cases a lateral or Stoppa approach was used.

The main type of osteosynthesis was a combination of plate and screw fixation in 71.9%. In 13 patients an isolated screw fixation was performed, in four of these combined by additional wire fixation. In 21 patients only plate fixation was performed, in one patient with an additive wire fixation. Four patients were treated primarily by osteosynthesis and total hip replacement.

The mean operative time was 287 ± 88 minutes (100-570 minutes), intraoperative blood loss averaged $1796 \pm 1130 \text{ ml}$ (200-6372 ml). The operative time and blood loss related to the type of surgical approach is shown in table 1.

Several articular lesions were recorded by preoperative and intraoperative assessment. 21 patients (15.6%) had injuries of the femoral head cartilage (10x cartilage contusions, 11x marginal impaction). Injury to the acetabular cartilage was seen in 45.2%. 48 patients (35.6%) had acetabular cartilage damage (3x cartilage contusions, 45x marginal impactions) and 32.6% had acetabular comminutions.

After primary internal fixation a congruent hip joint was seen in 94.7%. The average persistent displacement was $1.7 \pm 3 \text{ mm}$ (0 - 15 mm). An anatomical joint reconstruction (0-1mm) was achieved in 65.6% of patients, a near anatomical reconstruction (2-3mm) in 10% of patients and a poor reconstruction ($>3 \text{ mm}$) in 24.4%.

The incidence of postoperative seroma or hematoma requiring revision was 7.4%. Three patients (2.2%) developed a deep wound infection. These patients were treated after an average of 15 days by a combined approach.

Nerve injury

91.1% of patients with a both column fracture had no preoperative nerve injury. 8.9% of patients received a fracture related preoperative nerve damage. All but one patients (one lesion of the lateral cutaneous femoral nerve) had lesions of the peroneal part of the sciatic nerve. Postoperatively, 21 patients (15.6%) showed signs of a nerve deficit. In nine of ten patients with primary sciatic nerve damage the nerve deficit was found to be unchanged. One patient had complete recovery.

Iatrogenic nerve injury occurred in 12 patients (8.9%). Based on the selected approach, the incidence of iatrogenic nerve damage after Kocher-Langenbeck approach was 16.7%, after ilioinguinal approach 9.7%, after extended approaches 2.6% and after combined approaches 13.9%.

Long-term results

Of all 135 patients, one patient died secondary to an accident independent cause. Of the remaining, 89 patients (66.4%) could be followed after a mean of 54.6 ± 54.8 months (12-336 months).

The average subjective Visual Analog Scale pain score at follow-up was 27.6 ± 28.1 (0 - 88 points). The patients were rated by the examiner as having no pain in 33.7%, mild pain in 27%, moderate pain in 22.5% and severe pain in 16.8%.

The mean Merle d'Aubigné score was 15 ± 3.4 points (6-18 points) with 32.6% of patients with a perfect functional result, 28.1% with a good, 12.4% with a moderate and 27% a poor functional outcome.

A persistent nerve deficit was observed in 19 patients (21.3%): 10 patients had slight sensoric deficits, mainly involving the lateral cutaneous femoral nerve; four patients had motoric deficits of the peroneal part of the sciatic nerve (M3) and five patients had functionally disturbing deficits of the peroneal part of the sciatic nerve (M1, M2).

At follow-up 55 patients (61.8%) had no post-traumatic osteoarthritic changes of their hip joint (Fig. 2). 15 patients had mild changes (16.9%), eight patients (9%) had moderate arthritis and 11 patients had severe joint destructions (12.3%). Overall, femoral head necrosis grade III and IV were present in 10 patients, heterotopic ossification grade IV in three patients. In 19 patients after an average of 37.4 months postinjury a total hip replacement was necessary. Thus, a joint failure was diagnosed in 25.8% of the patients.

There was a significant correlation between the clinical (functional) and the radiological outcome ($p < 0.05$, chi-square test).

Considering only patients with anatomically reconstructed hip joints (postoperative gap/step: 0-1 mm) with

a complete follow-up (49.8 ± 47 months (12-233 months), $n = 63$) the following results could be observed:

38.1% of these patients complained of no, 31.7% of mild, 15.9% of moderate and 14.3% of severe pain. The mean Merle d'Aubigné score was 15.5 ± 3.3 points (6-18 points), with 38.1% having a perfect, 31.7% a good, 9.5% a moderate and 20.6% a poor functional result. Disturbing nerve damages (M1-M3) were present in 12.7% of these patients.

Post-traumatic arthrosic changes grade III or IV developed in 17.5% of these patients. A joint failure was present in 25.4%. Overall, 20.6% had total hip replacement. Comparing patient groups with a joint failure and no joint failure, patients developing a joint failure were significantly more likely to present with a lesion of the femoral head (37.5% vs. 10.6%, Fisher's exact test, $p < 0.02$). Also, a significant difference of primary articular fracture displacement was seen: 13.9 mm vs. 8.7 mm, Student's t test, $p < 0.005$). Other parameters showed no significant difference between these two groups.

DISCUSSION

Both column fractures of the acetabulum are common acetabular fracture types with an incidence of approxi-

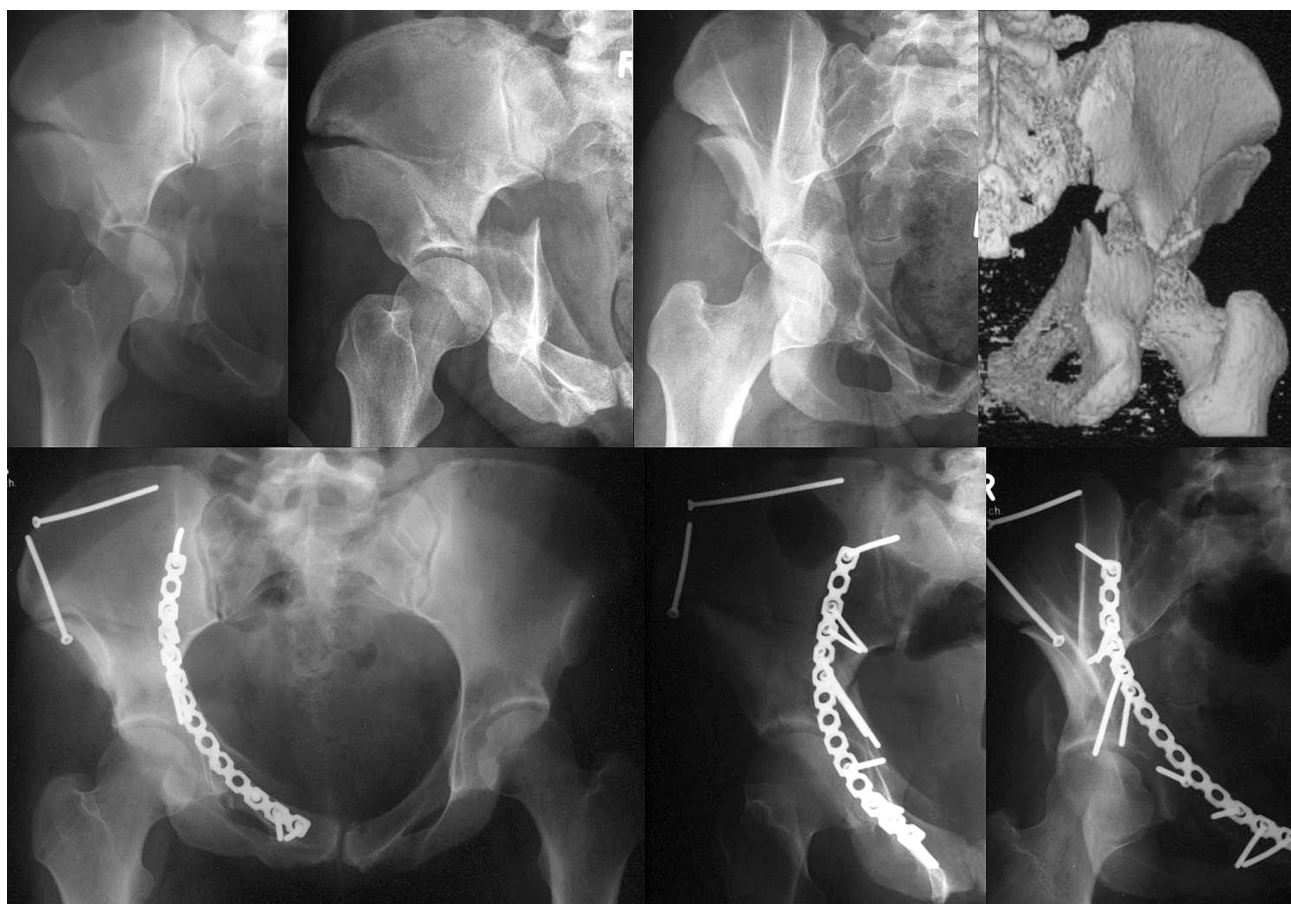


Fig. 2. Clinical example of a both column fracture treated with plate and screw osteosynthesis via the ilioinguinal approach with a congruent reconstruction of the joint.

mately 22% according to Letournel (9). Nevertheless, there are only few epidemiological data of this fracture type or long-term results. So far, only two studies were published that deal specifically with this fracture type (6, 12).

Chen et al. analyzed 35 consecutive patients with displaced both column fractures of the acetabulum (6). The average age was 43 years (19-72 years), 22 patients were male and 13 female. In 16 patients the right hip joint was involved and in 19 patients the left side. The cause of injury was a motor vehicle accident in 16 cases and a fall from a great height in 12 cases. 20% had concomitant injuries. A preoperative nerve deficit was not observed. Three patients had an acetabular Morel-Levalle lesion. The patients were surgically stabilized using plates, screws and wires via the Triradiate approach (16). The mean intraoperative blood loss was 1300 ml (800-3200 ml), the duration of the operation at about 300 minutes. Follow-up was performed on average after 40 months (18-69 months). The patients had a mean Harris hip score of 89 points (85-97 points), corresponding to a good to excellent results in all patients. Post-traumatic radiographic changes such as osteoarthritis or femoral head necrosis were not observed. Complications occurred in 7 patients (20%). There were two subcutaneous hematoma requiring revision, two superficial wound infections and three Grade I heterotopic ossifications. Iatrogenic nerve damage was not observed.

Masahiro et al. reported on 13 patients (10 men, 3 women) treated operatively with an average age of 47.9 years (12). ORIF was performed on average after 14.3 days. The blood loss was 1300-3520 ml, the duration of the operation was 240-470 minutes. The patients were reexamined after an average of 27 months. Radiographically, one patient had a radiologically poor and two an unsatisfactory result.

The remaining data in the literature are incomplete and can only be determined based on published large patient series.

Letournel reported an incidence of this fracture type of 22.7% (11). Overall, he reported on 213 of these fractures. The sex ratio was 1:1. An existing preoperative nerve lesion was present in 6.6% of cases.

158 of his patients were stabilized operatively within three weeks. In 31 cases (19.6%) the Kocher-Langenbeck approach was used, in 80 cases the ilioinguinal approach (50.6%) and in 29 cases the extended iliofemoral approach was used (18.4%). In 15 cases, a combined dorsal-ventral approach was chosen. An anatomical joint reconstruction was achieved in 60.8% of these cases.

Tab. 1. Operation time and intraoperative blood loss depend on the chosen approach

Approach	Operation time (min)	Blood loss (ml)
Kocher-Langenbeck	260 ± 93	1340 ± 800
Ilioinguinal	234 ± 56	1335 ± 845
Extended approach	339 ± 73	2220 ± 1316
Combined	306 ± 97	1705 ± 956

Clinical and radiological results were available for 135 patients (follow-up rate: 85.4%). 71.9% of patients had an excellent result (Merle d'Aubigné score), 10.4% a good, 8.1% a moderate and 9.6% a bad result. Thus, the frequency of good to excellent clinical results was 82.3%. Radiologically, there were 56.3% perfect results. Femoral head necrosis was not reported. 22.2% of these patients developed post-traumatic osteoarthritis. Six patients (4.4%) showed a malunion of the fracture.

Mears et al. reported on 102 both column fractures, of which 54.5% were anatomically and 20.8% near anatomically reduced (17). 12 patients had a non-anatomic joint reconstruction at 13 had a secondary joint congruency.

All patients were followed (100%) and Harris Hip Score (10) showed 70% good to excellent clinical results.

In a collective of 262 operatively treated acetabular fractures reported by Matta et al. 92 had a both column fracture (35.1%) (13).

One patient was stabilized via the Kocher-Langenbeck approach alone or combined with an ilioinguinal approach. In 59% of these patients the ilioinguinal approach was used and in 39% of the extended iliofemoral approach. An anatomical reduction was achieved in 57% of patients, a near anatomic reduction in 26% and 10% had non-anatomical joint reconstruction. In seven cases a secondary joint congruence was achieved. According to the Merle d'Aubigné score a functionally perfect result was found in 39%, a good in 38%, a moderate in 10% and poor in 13%.

Zinghi et al. found an incidence of this fracture type of 20.8% (26). The majority of the 106 patients were men. The rate of preoperative nerve deficits was 2.8%.

All patients were stabilized surgically. Three iatrogenic nerve injuries were reported (2.8%). Two patients developed deep hip joint infections (1.9%). Heterotopic ossifications of Brooker grade III and IV (4) were found in 7.5% and interestingly 23.6% of these patients developed an algodystrophic syndrome. Posttraumatic femoral head necrosis developed in 11.3%, acetabular necrosis in 7.5% and post-traumatic arthrosis in 11.3%.

The clinical result using the Merle d'Aubigné score showed a rate of excellent and good functional results in 66%, with 30 patients having an excellent and 40 a good result. 10 patients had moderate and 26 severe functional limitations.

Data from the 1st German Multicenter Study group pelvis reported an incidence of 20.3% for this fracture type (102/503 cases) (22). In 57 patients the fracture was stabilized surgically (55.9%). The Kocher-Langenbeck approach was used in 20 patients, the ilioinguinal approach in 17 patients, an extended approach in 11 patients and a combined dorso-ventral stabilization in 7 patients. In two patients, a Smith-Petersen approach was chosen.

The postoperative quality of reduction was evaluated as anatomic in 68.4%, as near anatomic in 19.3% and as non-anatomical in 15.1%.

Tab. 2. Relevant epidemiological data in operatively treated both column fractures

	Incidence (%)	Age	Sex m:f	Side r:l	High energy-trauma	Additional injuries	Primary nerve deficit (%)
Chen, n = 35	n.e.	43	22:13	16:19	28	7	0
Masahuri, n = 13	n.e.	47,9	10:3	n.e.	n.e.	n.e.	n.e.
Letournel, n = 213	22,7	n.e.	1:1	n.e.	n.e.	n.e.	6,6
Matta, n = 92	35,1	n.e.	n.e.	n.e.	n.e.	n.e.	n.e.
Zinghi, n = 106	20,8	n.e.	n.e.	n.e.	n.e.	n.e.	2,8
Pohlemann, n = 102	20,3	n.e.	n.e.	n.e.	n.e.	n.e.	n.e.
Gänsslen, n = 135	19,8	40,2	92:43	87:48	118	77	8,9
Overall	20	41,6	232:45:00	103:67	146/170	84/170	0 – 8,9

Tab. 3. Overview of perioperative data in both column fractures

	OR time	Approach				Duration of operation (min)	Blood loss (ml)
		ilioinguinal	Kocher-L	extended	combined		
Chen, n = 35	n.e.	0	0	35	0	300	1300
Masahuri, n = 13	14,3d	0	0	13	0	240-470	1300-3520
Letournel, n = 158	0-21d	80	31	29	15	n.e.	n.e.
Matta, n = 92	0-21d	54	1	36	1	n.e.	n.e.
Pohlemann, n = 57	n.e.	17	20	11	7	n.e.	n.e.
Gänsslen, n = 135	9,6d	31	18	39	36	287	1796
Overall	10,1d	182	70	163	59	289	1693

Tab. 4. Overview of the reduction quality in both column fractures

	Anatomic 0–1 mm	Near anatomic 2–3 mm	Non-anatomic <3 mm	Sec. congruency
Letournel, n = 158	96	n.e.	n.e.	n.e.
Matta, n = 92	52	24	9	7
Mears, n = 102	56	21	12	13
Pohlemann, n = 57	39	11	7	n.e.
Gänsslen, n = 131	86	13	32	n.e.
Overall	60,9 % (329/540)	18,1 % (69/382)	15,7 % (60/382)	10,3 % (20/194)

Tab. 5 Overview of functional and radiological long-term results after operative treatment of both column fractures

	Merle d'Aubigné				Postraumatic changes III+IV°	Femoral head necrosis
	18	16-17	13-15	<13		
Masahuri, n = 13	n.e.	n.e.	n.e.	n.e.	3	n.e.
Letournel, n = 135	97	14	11	13	30	0
Matta, n = 92	36	35	9	12	n.e.	n.e.
Zinghi, n = 106	30	40	10	26	19	12
Gänsslen, n = 89	29	25	11	24	18	10
Overall	192	114	41	75	70	22

Only 13 patients could be reexamined. At follow-up three patients were pain-free. Four patients complained of mild and six of moderate pain.

Due to lack of differentiation between surgical and non-surgically treated patients, no clear data were available on the long-term outcome after surgical treatment.

An unusual complication of this fracture type was reported by Chen et al. who observed two patients with damage to the internal iliac artery (5).

In summary, based on present available data from the literature and on the basis of the presented data the following conclusions can be made (see Tab. 2–5).

Epidemiological data (Tab. 2):

- the incidence of both column fractures is about 20%,
- the mean patient age is 41.6 years,

- the sex ratio is 1.4:1 (male: female),
- the hip-side ratio is 1.5:1 (right: left),
- high energy trauma as the cause of injury can be observed in up to 86%,
- the incidence of associated injuries is approximately 50%,
- the rate of primary nerve damage (especially sciatic nerve lesions) is from 0-8.9%.

Perioperative details (Tab. 3):

- the majority of patients is treated operatively within 3 weeks after trauma
- standard approaches were the ilioinguinal (38.4%) and extended approaches (34.4%), whereas the Kocher-Langenbeck approach was used in 14.8% and a combined approach in of 12.4%,

- in 70-80% a combined plate and screw fixation was performed,
- a mean operative time of 290 minutes can be expected,
- a mean intraoperative blood loss of 1700 ml can be expected.

Quality of reduction (Tab. 4):

A total of 61% anatomical reductions in both column fractures can be expected. Near anatomical reductions are observed in about 18% and non-anatomical reductions in about 21%, while in the latter group a rate of 25% secondary congruences were observed.

Complications (6, 26) and own results):

- the rate of postoperative hematoma/seroma requiring surgery is 7%,
- the rate of wound infections (superficial + deep, requiring surgery) is 2.5%,
- iatrogenic nerve injuries are observed in 5.4%.

Long-term results (Tab. 5):

- 45.5% perfect functional results can be expected,
- 27% good functional results can be expected,
- 9.7% moderate functional results can be expected,
- 17.8% poor functional results can be expected,
- overall, 72.5% good and perfect functional results can be expected,
- a rate of 20.4% posttraumatic arthritic changes can be expected after 60 month postoperatively,
- a rate of 6.7% posttraumatic femoral head necrosis can be expected after 60 month postoperatively.

CONCLUSION

Prognostic factors for a poor radiological and functional outcome in the present study were a concomitant injury of the femoral head (impaction, contusion) and a primary articular displacement of >10 mm.

This additional joint damage points out the potentially high kinetic energy acting to the hip joint at the moment of the accident.

References

1. AHO, A., ISBERG, U., KATEVUO, V.: Acetabular posterior wall fracture – 38 cases followed for 5 years. *Acta Orthop. Scand.*, 57: 101–105, 1986.
2. BAKER, S., O NEILL, B.: The injury severity score: an update. *J. Trauma*, 16: 882–885, 1976.
3. BOSCH, U., POHLEMANN, T., HAAS, N., TSCHERNE, H.: Klassifikation und Management des komplexen Beckentraumas. *Unfallchirurg*, 95: 189–196, 1992.
4. BROOKER, A. et al.: Ectopic ossification following total hip replacement: incidence and a method of classification. *J. Bone Jt Surg.* 55-A: 1629–1632, 1973.
5. CHEN, A. L., WOLINSKY, P. R., TEJWANI, N. C.: Hypogastric artery disruption associated with acetabular fracture. A report of two cases. *J. Bone Jt Surg.* 85-A: 333–338, 2003.
6. CHEN, C., CHIU, F., LO, W., CHUNG, T.: Cerclage wiring in displaced both column fractures of the acetabulum. *Injury*, 32: 391–394, 2001.
7. DEBRUNNER, H.: *Orthopädisches Diagnostikum*. 5. Aufl., Thieme, Stuttgart, New York, 34, 1987.
8. FICAT, R., ARLET, J.: Ischemia and necrosis of bone. Williams & Wilkins, Baltimore London, 1980.
9. GIANNOUDIS, P. V., GROTZ, M. R., PAPAKOSTIDIS, C., DINOPOULOS, H.: Operative treatment of displaced fractures of the acetabulum. A meta-analysis. *J. Bone Jt Surg.*, 87-B: 2–9, 2005.
10. HARRIS, H.: Traumatic Arthritis of the hip after dislocation and acetabular fractures: Treatment by mold arthroplasty. An end result study using a new method of result evaluation. *J. Bone Jt Surg.*, 51-A: 737–755, 1969.
11. LETOURNEL, E., JUDET, R.: *Fractures of the acetabulum*. 2nd ed., Berlin Heidelberg New York: Springer-Verlag, 1993.
12. MASAHIRO, S., KENSEI, N., KENSUKE, S., KUNIIHIKO, T., TAKANOBU, A., TOSHIYA, E., KMANABU, K., MASABUMI, I., TOMOYA, U.: Operative treatment of both column fractures in the acetabulum. *Orthop. Traumatol.*, 51: 162–167, 2002.
13. MATTA, J.: Fractures of the acetabulum: accuracy of reduction and clinical results of fractures operated within three weeks after the injury. *J. Bone Jt Surg.*, 78-A: 1632–1645, 1996.
14. MATTA, J., ANDERSON, L., EPSTEIN, H., HENDRICKS, P.: Fractures of the acetabulum: a retrospective analysis. *Clin. Orthop.*, 205: 230–240, 1986.
15. MATTA, J., MEHNE, D., ROFFI, R.: Fractures of the acetabulum: early results of a prospective study. *Clin. Orthop.*, 186: 241–250, 1986.
16. MEARS, D., MACLEOD, M.: Acetabular fractures: triradiate and modified triradiate approaches. in: WISS, D. A., *Master techniques in orthopaedic Surgery: Fractures*, 697–724, 1998.
17. MEARS, D. C., VELYVIS, J. H., CHANG, C. P.: Displaced acetabular fractures managed operatively: indicators of outcome. *Clin. Orthop.*, 407: 173–186, 2003.
18. MERLE D'AUBIGNE, M.: Traitement chirurgical de la coxarthrie. *Soc. Intern. de Chirurgie Orthopaedique*, 240–247, 1948.
19. MOED, B. R., WILLSONCARR, S. E., WATSON, J. T.: Results of operative treatment of fractures of the posterior wall of the acetabulum. *J. Bone Jt Surg.*, 84-A: 752–758, 2002.
20. MOORE, E., COGBILL, T., MALANGONI, M., JURKOVICH, G., SHACKFORD, S., CHAMPION, H., McANNICH, J.: Organ injury scaling. *Surg. Clin. North Am.*, 75: 293–303, 1995.
21. OTA, Fracture and dislocation compendium. *J. Orthop. Trauma*, 10(Suppl. 1): 71–75, 1996.
22. POHLEMANN, T., GÄNSSLEN, A., HARTUNG, S.: Für die Arbeitsgruppe Becken: Beckenverletzungen/Pelvic injuries. Hefte zu „Der Unfallchirurg“, 1998. Heft 266.
23. ROMMENS, P., GIMENEZ, M., HESSMANN, M.: Is the posterior wall avulsion the simplest acetabular fracture? *Eur. J. Trauma*, 26: 144–154, 2000.
24. TEASDALE, G., JENETT, B.: Assessment of coma and impaired consciousness: a practical scale. *Lancet*, 2: 81–83, 1974.
25. TSCHERNE, H., REGEL, G., STURM, J., FRIEDL, H.: Schweregrad und Prioritäten bei Mehrfachverletzungen. *Chirurg*, 58: 631–640, 1987.
26. ZINGHI, G., BRICCOLI, A., BUNGARO, P., DAVOLI, O., PONZIANI, L., ROLLO, G., TRONO, M.: Chapter twelve: Fractures in several planes. in Zinghi, G. F.: *Fractures of the pelvis and acetabulum*, Thieme-Verlag, Stuttgart, 219–234, 2004.

Corresponding author:

Dr. med. Axel Gänsslen

Klinik für Unfallchirurgie, Orthopädie und Handchirurgie

Klinikum der Stadt Wolfsburg

Sauerbruchstraße 7

38440 Wolfsburg, Germany

E-mail: dr.gaensslen@gmx.de