

Long-Term Effects of Intravenous Iloprost Therapy in Patients with Bone Marrow Oedema of the Knee Joint

Dlouhodobý efekt intravenózní terapie iloprostem u pacientů s edémem kostní dřene v oblasti kolenního kloubu

T. ZIPPELIUS¹, G. MATZIOLIS¹, C. PERKA², M. PUTZIER², P. STRUBE¹; E. RÖHNER¹

¹ Orthopaedic Department, University Hospital Jena, Campus Eisenberg, Germany

² Department of Traumatology and Orthopaedics, Charité University Hospital Berlin, Germany

ABSTRACT

PURPOSE OF THE STUDY

Bone marrow oedema (BMO) syndrome is a multifactorial condition. Various conservative treatment options include analgesic therapy, immobilisation of the affected joint and/or systemic intravenous iloprost therapy. Many studies have confirmed the positive effect of iloprost therapy, but only after short-term follow-up. The purpose of this study was to show that treatment with iloprost leads to positive long-term functional and radiological outcomes for BMO of the knee.

MATERIAL AND METHODS

Fifteen patients with BMO of the knee joint, ARCO stage 1–2, were included in this study. Various questionnaires, the Lysholm Score, the SF-36, WOMAC, Knee Society Score, and a visual analogue pain scale (VAS), were evaluated before and after iloprost therapy. All patients underwent MRI for radiological follow-up three months after treatment.

RESULTS

Significant improvements were found in the Lysholm Score, SF-36, WOMAC and KSS. In 80% of patients, follow-up MRI after three months showed complete regression of the oedema. Three patients received additional surgery after a follow-up period of 33 ± 7 months.

CONCLUSIONS

Based on the positive results of our study, we recommend treatment with iloprost for BMO of the knee in ARCO stage 1–2 patients.

Key words: iloprost, bone marrow oedema, knee joint.

INTRODUCTION

Bone marrow oedema of the knee joint is a painful multifactorial disease, which in the event of failed treatment can lead to osteoarthritis and the need for an artificial knee replacement (7). Whereas risk factors such as obesity, smoking, alcohol abuse and cortisone therapy appear to play a greater role in the case of the shoulder or hip joint, it is trauma and microfractures that tend to be responsible for the development of BMO in the knee joint. In contrast to BME of the hip joint, studies of BME of the knee joint are rare documented. The concepts applied to treat BMO involve a stage-dependent therapy. This may be conservative in the initial stage ARCO 1 and 2, whereas an appropriate surgical procedure should be applied in the advanced stage ARCO 3 and 4 (9, 14).

Conservative treatment includes relief of the respective joint, on the one hand, while pharmacotherapy with NSAIDs and/or intravenous iloprost therapy should be given, on the other. The vasodilator prostaglandin derivative iloprost (PGI₂) is used in various fields of medicine. The clinical field of application ranges from peripheral vascular disease, systemic sclerosis, diabetic angiopathy, pulmonary hypertension to the use after organ transplants (4, 6, 12, 13). The effectiveness of monoclonal antibodies such as denosumab or a bisphosphonate therapy has yet to be sufficiently confirmed in the literature.

Limited investigations have demonstrated that iloprost can be successfully used to treat the knee joint (1, 11). For example, the research group of Baier et al. showed

that pain relief, improved function and remission of the BMO according to MRI occurred after intravenous therapy with iloprost. Follow-up examinations were performed after 3 and 12 months (1). Like many other studies, the one conducted by Baier et al. showed good outcomes of iloprost therapy, but only after a short follow-up period of a few months (1).

The objective of the present study was to investigate the long-term course after intravenous iloprost therapy. The hypothesis of the study is that patients with BMO in the initial stage ARCO 1 and 2 who have been treated with iloprost also benefit after a long follow-up period, without the application of an additional surgical procedure.

MATERIAL AND METHODS

Fifteen patients with BMO of the knee joint, ARCO stage 1–2, were included in this retrospective study. They received a 5-day course of iloprost therapy at a concentration of 0.5 ng/kg/min over 6 hours according to a treatment schedule (Ilomedin; Bayer Schering, Germany).

All patients had BMO of the knee and met the following inclusion criteria: BMO confirmed by MRI, age 18 years or older, no history of knee trauma, pain in affected joint, no medical objections to therapy. According to the Association Research Circulation Osseous (ARCO) classification, visible BMO in MRI without pathological signs in CT or radiography was assessed as ARCO stage 1, and visible BMO in MRI with signs of sclerosis in CT and minor osteolysis and signs of sclerosis in radiography was assessed as ARCO stage 2.

All patients with ARCO stage 3 or 4 oedema, cardiac arrhythmia, atrial fibrillation or pulmonary hypertension, blood coagulation disorders, chronic infectious diseases, pregnancy, tumour diseases, or who were under the age of 18 years, were excluded from the investigation.

Questionnaires with validated scores were used before and after iloprost therapy:

- **Lysholm Score:** The Lysholm Score or modified Lysholm Score is a questionnaire that provides information about knee pain and/or the ability to manage everyday life. The Lysholm Score does not include assessments of radiographs.
- **SF-36:** The SF-36 (Short Form-36) is a questionnaire consisting of 36 questions and provides a statement about medical outcomes. It is used to assess various aspects of a patient's health, including general, physical and mental health, pain, social functioning, limitations from physical and emotional problems, fatigue or energy.
- **WOMAC:** Western Ontario and McMaster Universities Osteoarthritis Index (WOMAC) is a questionnaire used to evaluate pain, stiffness and function in patients with hip or knee osteoarthritis. WOMAC does not include assessments of radiographs.
- **KSS:** The Knee Society Score is an objective score system used to investigate outcomes of total or partial knee arthroplasty. It contains parameters such as knee

and patient's functional abilities including walking and stair climbing before and after TKA. KSS does not include assessments of radiographs.

- **VAS:** The visual analogue scale (VAS) is a rating used to quantify the patient's pain. Patients are instructed to make a mark on a line that corresponds to the level of their pain. The left end of this line represents no pain and the right end of the line represents maximum pain.

Post iloprost therapy, all patients were instructed to bear partial weight with a maximum of 20 kp on the affected joint for 6 weeks using two forearm crutches. Follow-up investigations were undertaken after 3 months. The follow-up MRI was conducted 3 months after iloprost treatment in all cases.

Ethics

The study had the approval of the local ethics committee of the Charite Berlin (EA1/209/16).

Statistics

Statistical tests were performed using Graph Pad Prism Software (Graph Pad Software, San Diego, USA). Statistical differences were verified using a paired t-test. Probability values of $p < 0.05$ were considered to be statistically significant; * $p < 0.05$ and ** $p < 0.01$. Data are shown as mean \pm standard error of the mean (SEM).

RESULTS

All of the patients included in the study tolerated the 5-day intravenous iloprost therapy without significant

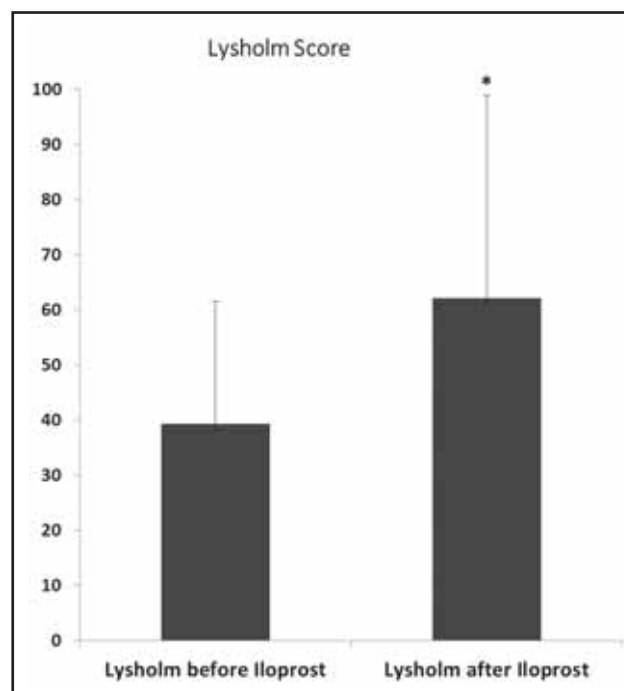


Fig. 1. It shows a significant improvement of Lysholm Score after iloprost therapy from 39 ± 22 points before to 62 ± 37 points after, $p < 0.05$.

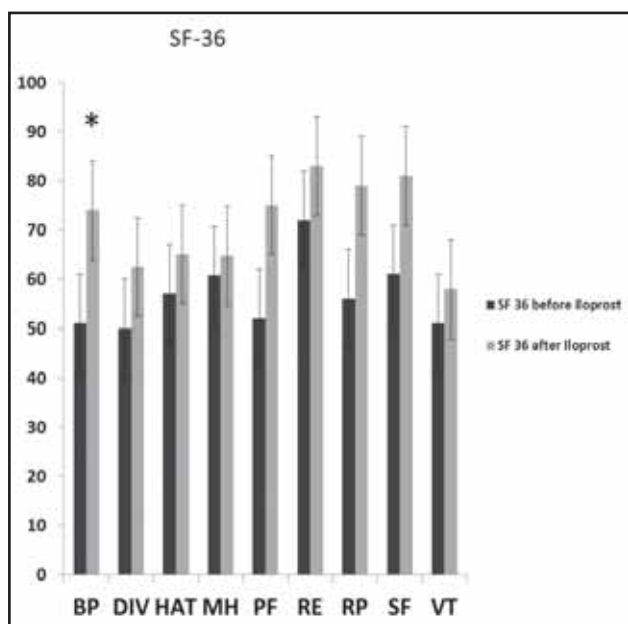


Fig. 2. The SF-36 score showed a significant increase for the parameter Bodily pain (BP): extent of pain and its effect on work from 51 to 74 point, $p < 0.05$ after iloprost therapy.

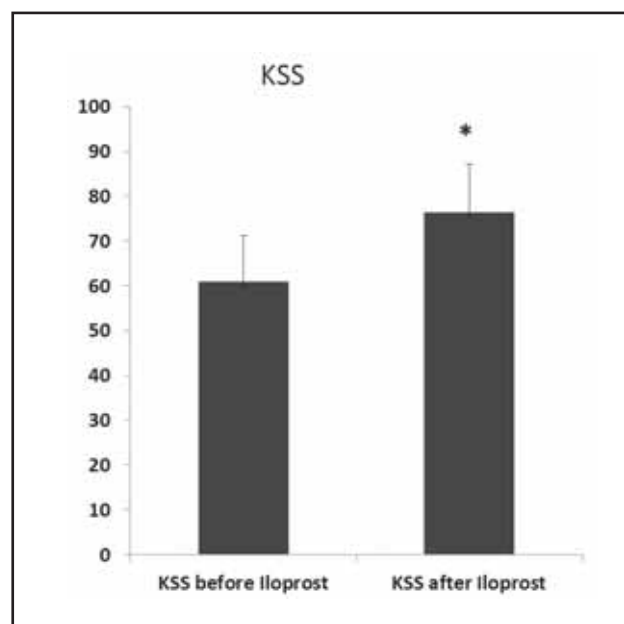


Fig. 3. The KSS demonstrated a significant improvement from 61 ± 10 to 76 ± 11 point, $p < 0.05$ after therapy with iloprost.

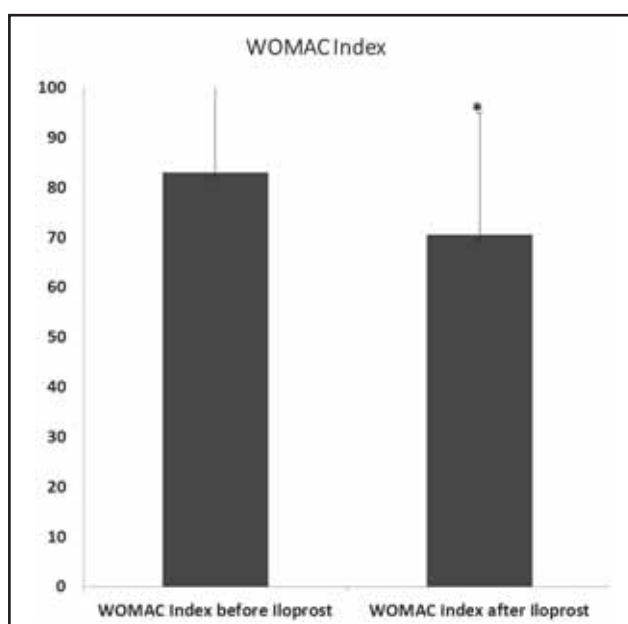


Fig. 4. For the WOMAC index, we observed a significant improvement from 83 ± 20 to 71 ± 24 points, $p < 0.05$.

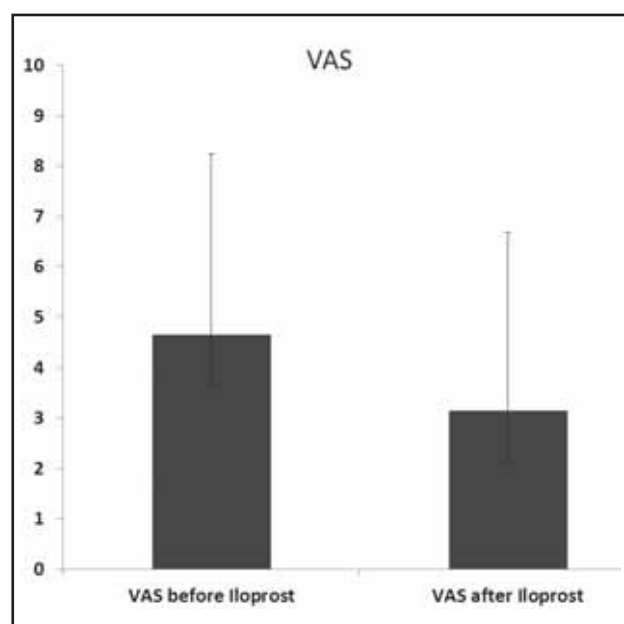


Fig. 5. A reduction in pain was seen after iloprost therapy in VAS (5 ± 4 points before in comparison with 3 ± 4 points after).

side effects. An improvement in all scores was found 33 ± 7 months after iloprost therapy. Significant improvement was confirmed in the Lysholm Score, SF-36 score in the area of bodily pain (BP), in the WOMAC Index and in the KSS. The Lysholm Score improved from 39 ± 22 before iloprost therapy to 62 ± 37 points after iloprost therapy ($p < 0.05$) (Fig. 1). The SF-36 score in the area of bodily pain (BP) showed an improvement from 51 to 74 points after iloprost therapy ($p < 0.05$) (Fig. 2). The KSS improved from 61 ± 10 to

76 ± 11 points after the treatment with iloprost ($p < 0.05$) (Fig. 3). In the WOMAC Index, an improvement from 83 ± 20 to 71 ± 24 points after iloprost therapy was demonstrated ($p < 0.05$) (Fig. 4). The VAS showed a pain reduction from 5 ± 4 to 3 ± 4 points (Fig. 5). Three patients underwent surgery over the course of the study. Two patients underwent retrograde drilling. One patient received a knee replacement. In 80% of the patients, no additional operation was performed during the study period.

DISCUSSION

The results of the present study confirm the positive effect of iloprost therapy in BMO of the knee stage ARCO 1 and 2 in long-term follow-up. In the present study, a significant improvement in function of the affected joint and a reduction of pain were achieved after iloprost therapy. Bone marrow oedema (BMO) of the knee joint is a common disease that particularly affects adults in their third, fourth or fifth decades of life. Studies observing the course of the disease show that the degenerative changes can lead to osteonecrosis and the need for consecutive endoprosthetic replacement (7). Early recognition of the symptoms and radiological diagnostics therefore play a central role, as does the question of the correct form of therapy (3, 5, 16). In the early stage of BMO, ARCO 1 and 2, both surgical and conservative therapeutic procedures are recommended. Precisely in BMO ARCO 1 and 2, conservative therapies show good results without additional operations (8, 10). An overview is given in table 1. Beside the administration of NSAIDs and relieving the affected joint, treatment with iloprost is a promising therapeutic procedure (11, 15).

In a randomised double-blind study conducted by Mayerhoefer et al., 41 patients with BMO of the knee joint were included. Twenty-one patients were treated with iloprost and twenty with tramadol. The treatment period was 4 weeks and the follow-up was 3 months. An improvement in the Larson Score from 58.6 to 81.8 was observed in the iloprost group. In MRI, a complete remission of BMO was seen in 53% of the included patients who had received iloprost treatment. In conclusion, no significant difference in analgesic effect between the two groups was observed, but a marked superiority of iloprost in the remission rate of BMO was seen in the follow-up MRI (10).

In a further study conducted by Jäger et al., 50 patients with BMO of the hip, knee, shoulder and foot were included, with a total of 117 affected bones. All patients received a 5-day intravenous iloprost therapy. Follow-up examinations were performed after 3 and 6 months. A VAS, the Harris Hip Score and the Knee Society Score were recorded and an MRI performed before iloprost therapy as well as 3 and 6 months after iloprost therapy. The VAS showed a marked improvement from 5.3 before iloprost therapy to 2 after 3 months and 1.8 after 6 months. All functional scores showed an improvement. The KSS improved from 112.8 points before iloprost therapy to 154.7 points after 3 months and 186.4 points after 6 months. Patients with higher grade ARCO stage 3 and 4 benefited markedly less from iloprost therapy (8). Here, an appropriate surgical procedure should be considered.

Both of the studies presented above showed a positive effect after iloprost therapy, but over a very short follow-up interval. Here, we were able to demonstrate a positive effect of iloprost after a long follow-up period of on average 33 months. All of the functional scores

recorded showed a significant improvement. Surprisingly, no significant improvement could be demonstrated with regard to pain. This is attributable above all to the large spread of values obtained with the VAS. Nevertheless, a reduction in pain was achieved in all patients.

In more recent studies, a superiority of iloprost therapy in combination with surgery has been shown (2).

In a study conducted by Beckmann J et al., 36 patients with BMO on the femoral head were included. 12 patients received intravenous iloprost therapy, 12 patients underwent retrograde drilling and 12 patients were given a combination therapy consisting of drilling and iloprost therapy. In all groups, an improvement in function and pain activity was seen, whereby the best results were achieved in those patients who had received the combination therapy of retrograde drilling and iloprost therapy (2).

Despite the superior results of the combination therapy consisting of retrograde drilling and iloprost therapy, it must still be pointed out that the patients have to accept the risks attached to surgery here. Therefore, the choice of therapy should be decided strictly according to the stage and the patient should be informed precisely about the different treatment options (9, 14).

The limitations of the present study are its retrospective design, the relatively small number of cases and the lack of a control group.

CONCLUSIONS

Nevertheless, the present investigation shows that patients with a BMO of the knee joint who received intravenous iloprost therapy significantly benefited over the long-term course. On the basis of our results, intravenous iloprost therapy represents a suitable treatment option for bone marrow oedema in the area of the knee joint in ARCO stage I and II.

Compliance with ethical standards

Conflict of interest None.

References

1. Baier C, Schaumburger J, Götz J, Heers G, Schmidt T, Grifka J, Beckmann J. Bisphosphonates or prostacyclin in the treatment of bone-marrow oedema syndrome of the knee and foot. *Rheumatol Int.* 2013;33:1397–1402.
2. Bartl C, Imhoff A, Bartl R. Treatment of bone marrow edema syndrome with intravenous ibandronate. *Arch Orthop Trauma Surg.* 2012;132:1781–1788.
3. Breitensteiner MJ, Kramer J, Mayerhoefer ME, Aigner N, Hofmann S. [Differential diagnosis of bone marrow edema of the knee joint]. *Radiologe.* 2006;46:46–54.
4. Cestelli V, Manfredi A, Sebastiani M, Praino E, Cannarile F, Giuggioli D, Ferri C. Effect of treatment with iloprost with or without bosentan on nailfold videocapillaroscopic alterations in patients with systemic sclerosis. *Mod Rheumatol.* 2017;1:110–114.

5. Elder GJ. From marrow oedema to osteonecrosis: common paths in the development of post-transplant bone pain. *Nephrology*. 2006;11:560–567.
6. Elraiyah T, Tsapas A, Prutsky G, Domecq JP, Hasan R, Firwana B, Nabhan M, Prokop L, Hingorani A, Claus PL, Steinkraus LW, Murad MH. A systematic review and meta-analysis of adjunctive therapies in diabetic foot ulcers. *J Vasc Surg*. 2016; 63:46S–58S.e41–42.
7. Felson DT, McLaughlin S, Goggins J, LaValley MP, Gale ME, Totterman S, Li W, Hill C, Gale D. Bone marrow edema and its relation to progression of knee osteoarthritis. *Ann Intern Med*. 2003;139:330–336.
8. Jäger M, Tillmann FP, Thornhill TS, Mahmoudi M, Blondin D, Hetzel GR, Zilkens C, Krauspe R. (2008) Rationale for prostaglandin I₂ in bone marrow oedema –from theory to application. *Arthritis Res Ther*. 2008;10:R120.
9. Maus U, Roth A, Tingart M, Rader C, Jäger M, Nöth U, Reppenhagen S, Heiss C, Beckmann J. (S3 Guideline. Part 3: Non-Traumatic Avascular Necrosis in Adults - Surgical Treatment of Atraumatic Avascular Femoral Head Necrosis in Adults). *Z Orthop Unfall*. 2015;153:498–507.
10. Mayerhoefer ME, Kramer J, Breitenheiser MJ, Norden C, Vakil-Adli A, Hofmann S, Meizer R, Siedentop H, Landsiedl F, Aigner N. Short-term outcome of painful bone marrow oedema of the knee following oral treatment with iloprost or tramadol: results of an exploratory phase II study of 41 patients. *Rheumatology*. 2007;46:1460–1465.
11. Meizer R, Radda C, Stolz G, Kotsaris S, Petje G, Krasny C, Wlk M, Mayerhöfer M, Landsiedl F, Aigner N. MRI-controlled analysis of 104 patients with painful bone marrow edema in different joint localizations treated with the prostacyclin analogue iloprost. *Wien Klin Wochenschr*. 2005;117:278–286.
12. Prior DL, Adams H, Williams TJ. Update on pharmacotherapy for pulmonary hypertension. *Med J Aust*. 2016;205:271–276.
13. Riemekasten G, Beissert S, Distler JH, Kreuter A, Müller-Ladner U. [Digital ulcers in systemic sclerosis : A retrospective health service study analysing treatment with bosentan and other vasoactive therapies]. *Z Rheumatol*. 2017;76:227–237.
14. Roth A, Beckmann J, Smolenski U, Fischer A, Jäger M, Tingart M, Rader C, Peters KM, Reppenhagen S, Nöth U, Heiss C, Maus U. [S3 guideline. Part 2: Non-traumatic avascular femoral head necrosis in adults – untreated course and conservative treatment]. *Z Orthop Unfall*. 2015; 153:488–497.
15. Röhner E, Zippelius T, Steindl D, Fussi J, Perka C. Effects of intravenous iloprost therapy in patients with bone marrow oedema of the foot and ankle. *Eur J Orthop Surg Traumatol*. 2014;24:1609–1616.
16. Vande Berg B, Lecouvet F, Koutassisoff S, Simoni R, Maldague B, Malghem J. Bone marrow edema of the femoral head. *JBR-BTR*. 2007;90:350–357.

Corresponding author

Timo Zippelius, MD

Orthopaedic Department, University Hospital Jena

Campus Eisenberg

Klosterlausnitzer Str. 81

07607 Eisenberg, Germany

E-mail: timo.zippelius@uni-jena.de