

# Sternal Fracture as a Risk Factor for Blunt Cardiac Injury

## Zlomenina hrudní kosti jako rizikový faktor tupého poranění srdce

**BARBORA VYHNÁNKOVÁ<sup>1,3</sup>, VALÉR DŽUPA<sup>2,3</sup>, ZDENĚK ŠUBRT<sup>1,3</sup>**

<sup>1</sup>Department of General Surgery, Third Faculty of Medicine Charles University and University Hospital Královské Vinohrady, Prague

<sup>2</sup>Department of Orthopaedics and Traumatology, Third Faculty of Medicine Charles University and University Hospital Královské Vinohrady, Prague

<sup>3</sup>Third Faculty of Medicine Charles University, Prague

Dedicated to the 70th anniversary of the birth of Prof. Martin Krbec, MD, CSc.

### Corresponding author:

MUDr. Barbora Vyhánková  
Department of General Surgery  
Third Faculty of Medicine Charles University  
and University Hospital Královské Vinohrady  
Šrobárova 1150/50  
100 34 Prague 10, Czech Republic

[barbora.vyhankova@fnkv.cz](mailto:barbora.vyhankova@fnkv.cz)

Vyhánková B, Džupa V, Šubrt Z. Sternal Fracture as a Risk Factor for Blunt Cardiac Injury. Acta Chir Orthop Traumatol Cech. 2026;93:178-188.

## SUMMARY

Motor vehicle collisions are the leading cause of blunt chest trauma, including blunt cardiac injury (BCI) and sternal fracture (SF). Blunt cardiac injury occurs in about 20% of blunt chest trauma reaching to 76% in polytrauma patients. Reported SF rates range from 1.6% to 42%. This review evaluates the link between SF and BCI with focus on incidence, diagnosis and implications for patient management.

A systematic search of the scientific literature in online databases over the past 15 years was conducted. The final set included 31 studies, predominantly retrospective, which were subsequently analyzed with emphasis on the definition of BCI, its occurrence and its association with SF.

BCI refers to a heterogeneous group of cardiac injuries resulting from a common traumatic mechanism. The term is often used interchangeably with myocardial contusion, thereby limiting the comparability of study results. Clinically significant injury can range from mild arrhythmias to cardiogenic shock, while some cases of BCI may remain completely asymptomatic. SF is common and indicates a substantial force to the chest. Patients are often categorized into two groups: those with an isolated sternal fracture, which is usually a benign injury without cardiac involvement, and those with a combined sternal fracture, which is common in polytrauma patients. The association between SF and BCI remains controversial. Some studies regard SF as a general indicator of overall trauma severity, whereas others identify it as an independent risk factor for BCI. There are multiple approaches

in diagnostics of BCI. Initial screening includes electrocardiography and monitoring of troponin I levels. If both are within normal limits, BCI is unlikely. Echocardiography is recommended for hemodynamically unstable patients or when initial test results are abnormal. Management includes continuous ECG monitoring, treatment of arrhythmias and analgesia.

Current recommendations support screening for BCI following blunt chest trauma. Evidence is mixed on whether SF alone predicts the presence of BCI. Further prospective studies using a uniform definition of BCI are required to confirm the clinical significance of SF in the diagnosis and patient prognosis. Physicians should maintain a high index of suspicion for BCI in patients after high-energy chest trauma.

**Key words:** sternal fracture, blunt cardiac injury, chest trauma.

## INTRODUCTION

Blunt chest trauma most often occurs in motor vehicle collisions (MVC), reported in up to 60% of cases (14). Other mechanisms include falls from height, crush injuries and physical assaults. MVC are also the leading cause of both, blunt cardiac injury (BCI) and sternal fracture (SF) (11, 18, 43, 45), and account for up to 90% of all SFs (1, 9, 45).

BCI is implicated in approximately 25% of post-traumatic deaths, according to autopsy studies (28, 40). The true incidence of BCI cannot be reliably determined, as some injuries remain asymptomatic and diagnostic criteria have not yet been established. Among patients admitted with blunt chest trauma, the incidence of BCI is approximately 20% (11)

and rises to as high as 76% in cases involving severe thoracic trauma or polytrauma (29, 40, 50).

Sternal fracture remains closely associated with BCI. Although several studies have considered SF to be a benign injury, particularly when isolated (1, 7, 21), its potential association with cardiac injury should not be overlooked. With the anterior chest impact the heart may be compressed between the sternum and the spine, while a concomitant fracture can directly damage the myocardium with the fragments or even perforate the chamber (27). The incidence of SF in patients with blunt chest trauma has ranged from 1.6% to 42% according to the literature over the past 15 years (9, 21, 29, 55).

The aim of this review is to evaluate studies from the past 15 years on the relationship between SF and BCI, focusing on incidence, diagnosis and the clinical relevance of SF for patient management.

## METHODOLOGY

The literature search was conducted in the PubMed and Google Scholar databases for the period 2011–2025. The following keywords and Boolean operators were used: (sternal fracture OR sternum fracture) AND (blunt cardiac injury OR cardiac contusion). A total of 1,010 articles were identified, 438 in PubMed and 572 in Google Scholar (Fig. 1).

Only articles meeting the following inclusion criteria were considered: those that mentioned both SF and BCI and were published in English. The following were excluded: studies focused on only one of the topics (BCI only or SF only); animal models; pediatric patients; injuries incurred during cardiopulmonary resuscitation; penetrating chest injuries; case reports; autopsy studies.

After excluding these studies, a total of 47 articles remained. This set consisted of retrospective and prospective studies, meta-analyses, and review articles. If a finding in a review article was directly cited from the original work and had not been updated with a new standpoint, the original work was retrieved, but the review was not included in the final list. After excluding these reviews, 31 studies were included, predominantly retrospective in design. In analyzing the studies, we focused on defining BCI, its incidence and its association with SF.

## DEFINITION AND PATHOPHYSIOLOGY OF BCI

The term BCI is often exchanged for cardiac or myocardial contusion. Histopathologically, myocardial contusion is defined as trauma-induced myocardial ecchymoses with ischemic and necrotic changes of the myocardium. Its definitive diagnosis can be made only postmortem (49). In surviving patients, a standardized diagnostic approach has not been

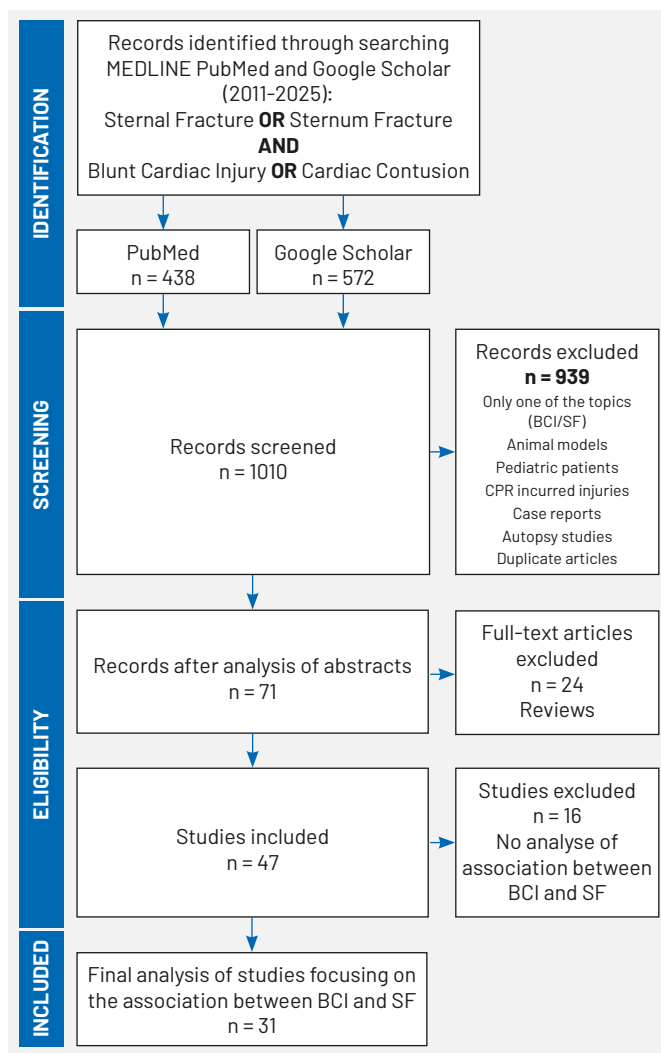


Fig. 1. Methodology diagram.

clearly established. Severe forms can be excluded using ECG, laboratory testing, echocardiography (ECHO) and others (6). If these tests are not performed, we cannot be certain that it is merely a contusion. For example, echocardiographic evidence of abnormal valvular motion, papillary muscle rupture or a septal laceration indicates more than just a simple contusion.

BCI is defined as any cardiac injury resulting from blunt mechanism of trauma (9). Marcolini and Keegan began their review with a quote from Burchell, "and always with a heart contusion arise both doubt and much confusion" underscoring the persistent ambiguity in definitions and the inconsistency of terminology (5, 29). It complicates further research as well as the accurate determination of incidence and diagnosis. Mattox et al. were the first to propose the elimination of the terms "cardiac contusion" and "cardiac concussion", suggesting instead the use of terminology based on the

Table 1. AAST Heart Injury grading scale (2)

GRADE I
1. Blunt cardiac injury with minor EKG abnormality (non specific ST of T wave changes, premature atrial or ventricular contractions, or persistent sinus tachycardia)
2. Blunt or penetrating pericardial wound without cardiac injury, tamponade, or cardiac herniation
GRADE II
1. Blunt cardiac injury with heart block or ischemic changes without cardiac failure
2. Penetrating tangential cardiac wound, up to but not extending through endocardium, without tamponade
GRADE III
1. Blunt cardiac injury with sustained or multifocal ventricular contractions
2. Blunt or penetrating cardiac injury with septal rupture, pulmonary or tricuspid incompetence, papillary muscle dysfunction, or distal coronary artery occlusion without cardiac failure
3. Blunt pericardial laceration with cardiac herniation
4. Blunt cardiac injury with cardiac failure
5. Penetrating tangential myocardial wound, up to but not through endocardium, with tamponade
GRADE IV
1. Blunt or penetrating cardiac injury with septal rupture, pulmonary or tricuspid incompetence, papillary muscle dysfunction, or distal coronary artery occlusion producing cardiac failure
2. Blunt or penetrating cardiac injury with aortic or mitral incompetence
3. Blunt or penetrating cardiac injury of the right ventricle, right or left atrium
GRADE V
1. Blunt or penetrating cardiac injury with proximal coronary artery occlusion
2. Blunt or penetrating left ventricular perforation
3. Stellate injuries, less than 50% tissue loss of the right ventricle, right or left atrium
GRADE IV
1. Blunt avulsion of the heart
2. Penetrating wound producing more than 50% tissue loss of a chamber

mechanism of injury, with further characterization according to the specific finding such as septal rupture, coronary artery dissection or arrhythmia (30). The American Association for the Surgery of Trauma defines BCI by its mechanism and categorizes it based on additional findings (Table 1)(2).

The nature of BCI depends on the anatomical location of the heart in the chest and on the filling of the cardiac chambers at the moment of trauma (17). Blunt chest trauma involves a direct impact on the chest, usually to the anterior wall, most often resulting from MVC, and it may cause compression of the heart between the sternum and the thoracic spine. Furthermore, additional mechanical forces may contribute to cardiac injury. Shoar et al. described these patterns (42):

- direct impact to the chest such as steering wheel trauma;
- sternal fracture leading to compression of the heart against the vertebral column;
- acceleration-deceleration impact leading to a torsion at the fixation sites such as the pulmonary trunk;
- hydraulic effect transmitting the increased intra-abdominal pressure to the right atrium via the draining inferior vena cava;
- blast injury.

The pathophysiology of BCI is also related to an interesting finding from a retrospective study of the Japan Trauma Data Bank, in which the authors investigated the association between BCI and the "type" of patient, that included drivers and passengers, motorcyclists, cyclists, pedestrians, falls from height and slips (18). Drivers showed a clear association with BCI, probably due to steering wheel impact. Gao et al. observed the same pattern (11). Another possible mechanism of cardiac injury in blunt chest trauma is direct injury caused by sharp fragments of the sternum or ribs (27), resulting in secondary cardiac damage.

The heart is most vulnerable at the end of diastole when the ventricles are fully filled (17). Autopsy-based studies report that the right ventricle is the most frequently injured cardiac chamber (up to 40%), due to its anterior position relative to the other cardiac chambers, followed by the right atrium (11, 47, 57). Other sites susceptible to injury are located at the junctions of the veins and the atria, where deceleration may cause tearing (47, 57).

Patients with BCI can be divided into two groups, those who die at the scene and those who survive long enough to reach the hospital. Fatal cases most often show transmural rupture of one or more chambers (64%), tears at the venoatrial junctions and coronary artery injury (47, 57). Survivors usually present with less severe forms of BCI, such as intramural hematoma, cardiac tamponade, valvular injury and coronary artery injury (including dissection, laceration or thrombosis) with infarction (38), a condition referred to as traumatic acute coronary syndrome (TACS) (11). Other findings include septal injury and arrhythmias (sinus tachycardia, atrial fibrillation, ventricular extrasystoles, AV blocks, ventricular tachyarrhythmias) (57).

## STERNAL FRACTURE

Sternal fracture commonly occurs as a result of blunt chest trauma caused by a direct impact or chest compression/flexion associated with spinal injury (41). Traffic accidents are the most common cause of SF (11, 32). Andrews and McAfee described SF as part of the "seat belt syndrome", an injury pattern related to the restraint by the three-point seat belt during a MVC, even before the mandatory installation of seat

belts in automobiles (3, 43). This finding was later confirmed by Porter and Zhao, who demonstrated that SF occurred predominantly in patients restrained by seat belts (39, 43). Other studies failed to confirm the effect of seat belts (7, 24), which may be explained by the blunt impact of unrestrained occupants against the steering wheel or airbag, producing similar injuries (24).

The sternum consists of the manubrium, the body, and the xiphoid process. Although the location of the fracture varies, several studies have shown that the fracture line most commonly involves the sternal body (up to 93% of cases) (45, 51). In contrast, Simsek et al. found that fractures most often occurred in the manubrium, which are typically caused by higher-energy mechanisms than fracture of the (anatomically wider) sternal body and were significantly associated with a higher incidence of pneumomediastinum, pneumothorax and hemothorax (41, 43). Son et al. reported that patients with manubrial fracture have a sevenfold higher risk of concomitant injuries (45). Scheyerer et al. noted that such patients had higher ISS, mortality rates and incidence of associated injuries (41).

Based on the studies, patients with SFs can be divided into two groups. The first group includes patients with an **isolated sternal fracture** (ISF), defined as a SF without any associated thoracic or abdominal injury, occurring in approximately 13–36% of cases (24, 28, 37, 55). The second group consists of patients with **combined sternal fractures** (CSF), in whom additional injuries are present, this group represents most cases and includes polytrauma patients (1, 35). The most frequently associated injuries in CSF are rib fractures, pulmonary contusions, pneumothorax, hemothorax and thoracic vertebral fractures (18, 35, 43, 45). The understanding of ISF has evolved over time. According to recent studies, ISF represents a benign condition that does not require admission to an intensive care unit (1, 24). Some authors have even suggested that these patients can be discharged home directly from the emergency department (7, 28, 49). The classification into these two clinical entities plays an important role in patient management and allows better allocation of healthcare resources (7, 34).

Because of the potential for associated injuries in SFs, computed tomography (CT) is considered the diagnostic modality of choice in patients with a significant trauma mechanism and suspected SF. The fracture may not always be visible on plain radiographs, thus sagittal 2D reconstruction is essential for precise diagnosis (37, 45). The availability of 2D and 3D reconstructions is gradually replacing the use of X-ray in this indication. CT also provides a higher detection and assessment of other thoracic injuries. CT has become an indispensable component of trauma center equipment, where hemodynamically stable patients after severe trauma undergo a “trauma protocol” (“pan-scan”). The growth in CT examinations is also responsible for rising incidence of SF (37),

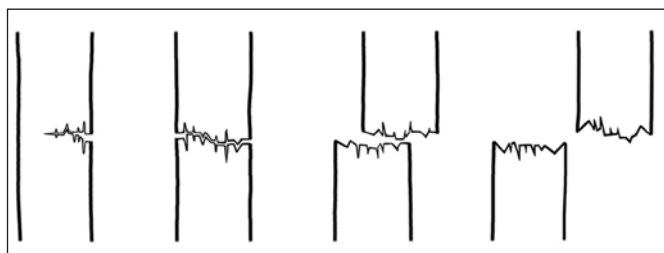


Fig. 2. Schematic illustration of the Johnson and Branfoot classification (author's illustration).

and not solely the seat belt legislation, as suggested by some authors (39, 51).

The Johnson and Branfoot classification (Fig. 2) divides SFs into four grades (20):

Grade I: fracture with incomplete thickness.

Grade II: full-thickness fracture, but without displacement.

Grade III: displaced fracture, without complete displacement.

Grade IV: completely displaced fracture, leading to sternal instability.

Another classification of SFs was published by the AO (Arbeitsgemeinschaft für Osteosynthesefragen) group in 2018. It divides SFs into three main groups according to their anatomical location (manubrium, body, xiphoid process) and then into subgroups according to the fracture line morphology (31).

## STERNAL FRACTURE AS A PREDICTOR OF BLUNT CARDIAC INJURY

Blunt thoracic trauma itself is a recognized risk factor for BCI (40). Consequently, the presence of a SF should warrant further diagnostic evaluation. The relationship between SF and BCI remains inconclusive in the literature. Analysis of studies from the last 15 years failed to demonstrate consistent evidence supporting this association.

Fokin et al. reported that no BCI occurred in patients with ISF. BCI was observed only in those with concomitant injuries (9). Similar findings were also reported by other authors (1, 7, 22, 23, 35, 56). A sternal fracture may merely serve as an indicator of significant force applied to the chest, which can result in injury to the surrounding structures, including the heart (12). Conversely, these findings suggest that an ISF reflects a less destructive impact mechanism and therefore a minimal risk of cardiac injury.

Heidelberg et al. demonstrated that displacement of a SF alone does not correlate with the incidence of BCI, physicians should, however, pay attention to concomitant injuries (15). According to Scheyerer et al., the location of the fracture line

is not associated with the occurrence of BCI (41). These findings were also confirmed by Uz et al (48).

Kuru and Sahinoglu reported a direct correlation in patients with SF: the more severe the injury, the higher the risk of BCI (25). Odell et al. found a very low incidence of BCI in patients with SFs, reaching only 1.8% (34). Saglam Gürmen and Tulay, Kunhivalappil et al., and Perez et al. reported no statistically significant correlation between SF and BCI (24, 37, 40).

Conversely, the study by Ishida et al. identified a significant positive association between SF and BCI based on multivariate logistic regression analysis. SF occurred in 12.7% of patients with BCI (18). Gao et al. confirmed an association between BCI and SF, in their analyzed cohort, 72% of patients with BCI had a SF. They also linked them through the mechanism of trauma, both injuries most frequently resulted from MVC (11).

Grigorian et al. analyzed the National Trauma Data Bank and identified SF as the second strongest independent predictor for BCI, after hemopneumothorax. Their results also demonstrated a correlation between the degree of SF displacement and the incidence of BCI (12). Comparable findings were reported by Hanschen et al. based on their trauma registry analysis. They reported a high incidence of SFs even in mild BCI (20% of patients) and identified SF as a strong predictor of BCI (14).

According to Jiang et al., the presence of SF was significantly associated with BCI, patients with SF had a sevenfold increased risk of BCI compared with those without. The authors regarded SF as an important warning indicator for BCI (19).

Clancy et al., in the Eastern Association for the Surgery of Trauma (EAST) guidelines, concluded that SF alone is not a reliable indicator of BCI, and monitoring or further diagnostic evaluation is not indicated if ECG and troponin I (TnI) values are normal. The diagnostic algorithm should be the same as for other patients with suspected BCI, independent of whether a SF is present (6).

## DIAGNOSIS OF BCI IN PATIENTS WITH STERNAL FRACTURE

The diagnosis of BCI is complicated by the variability in clinical, imaging and laboratory parameters across studies. Methods that have been used include ECG, various cardiac enzymes, echocardiography, chest CT and CT angiography, MRI and coronary angiography. Each method has its limitations, and a combination of several methods is often required to establish the diagnosis. Notably, the only definitive confirmation of BCI is obtained at autopsy (49).

The first question for the physician is when to suspect BCI. During the initial contact with a polytrauma patient in the emergency department, cardiac injury is rarely the first thing on physician's mind. A history of major trauma, including

high-speed MVC or falls from height, combined with chest injury should prompt suspicion of BCI (18, 32, 42). BCI frequently coexists with other thoracic injuries, including the chest wall trauma (SF, thoracic spine fracture, serial rib fractures) and intrathoracic lesions such as pulmonary contusion, hemothorax or pneumothorax (15, 49, 57). These associated injuries may suggest BCI; Hanschen et al. described them as "indicator injuries" warranting further cardiac evaluation (14).

**Clinical signs and symptoms** in such patients are frequently nonspecific. Patients report chest pain, dyspnea and palpitations. However, in many cases patients with BCI have concomitant injuries, whose symptoms may mask those of BCI, such as altered consciousness after head trauma (18). Physical examination may reveal signs of "seat belt injury" (anterior chest wall ecchymoses), as well as muffled heart sounds or murmurs, which are difficult to detect in the emergency department (29). Important are the symptoms of Beck's triad, which indicative of cardiac tamponade (increased jugular venous filling, hypotension, muffled heart sounds), and signs of shock that cannot be explained by hemorrhage. If the patient is hemodynamically unstable after a significant mechanism of trauma and does not respond to fluid resuscitation, a possible BCI should be considered (6, 14). On rare occasions, the squeezing anginal pain occurs, which may indicate TACS. Angina pectoris can be further specified by the simultaneous occurrence of palpitations, pallor, ECG changes and relief after nitroglycerin administration (11).

All these symptoms may be accompanied by hypotension (14, 18). According to Ishida et al., there is a significant association between BCI and hypotension at hospital admission. Post-traumatic chest hypotension may result from hypovolemic shock (hemorrhage), obstructive shock (cardiac tamponade, tension pneumothorax), cardiogenic shock (direct myocardial injury) or, rarely, distributive shock (thoracic spinal cord injury). The mechanism of BCI can produce a combination of these pathophysiological states (18).

Patients after severe chest trauma are examined using imaging methods, which may indicate the reason for closer cardiac evaluation. If the patient is hemodynamically stable, CT is usually performed, in cases of hemodynamic instability, FAST and bedside chest X-ray is indicated, according to ATLS recommendations (10).

A **twelve-lead ECG** is the primary screening method and should be performed in all patients with blunt chest trauma, especially with severe chest-wall injury (6, 52). According to Marcolini and Keegan, ECG should also be considered in patients without obvious chest injury if the mechanism of trauma places them at high risk for BCI (29). The most common abnormal ECG finding is supraventricular tachycardia, where pain and hypovolemia may be responsible for its persistence (15), other common findings are atrial fibrillation and ventricular extrasystoles. When such arrhythmias are detected, traumatic shock must first be excluded (29, 57). Other common

arrhythmias include bundle branch block, ST-segment deviation or atrioventricular block (9). ECG must be interpreted in the context of the patient's history, where some findings may be pre-existing. A negative ECG alone does not exclude BCI (6, 16, 29, 57). A normal ECG finding may be influenced by the location of the injury. Most commonly the right ventricle and the right atrium are injured, on the other hand ECG is more sensitive to trauma of the left ventricle due to its larger muscle volume (14).

Another basic screening test is measuring **cardiac enzymes**, which are routinely used to evaluate myocardial infarction and are released from the myocardium after injury. Creatine kinase and its CK-MB isoenzyme are neither sufficiently sensitive nor specific for the detection of BCI and are not recommended for diagnostic purposes (6, 14, 26, 46). In the past, there has been debate over whether troponin I (TnI) or troponin T (TnT) are more suitable for BCI detection. TnT carries a higher risk of false positive results. The concentration of its cardiac isoform may be confounded by the release of TnT from skeletal muscle. Furthermore, its concentration is affected by renal function, which may be impaired during the shock caused by trauma. For these reasons, many studies have used TnI (4, 40).

TnI therefore appears to be a much more specific marker of cardiac injury. The problem is that neither the optimal sampling time after trauma nor the threshold value at which BCI be suspected has been established (6). According to Saglam Gürmen et al., the main diagnostic time point is reassessment of TnI at 4 hours after the trauma. TnI levels remained elevated in patients with clinically significant BCI but normalized in the others (40). Further studies have confirmed the importance of repeated TnI measurement (26, 46). Velmahos et al. reported that the combination of a normal ECG and normal troponin levels at admission and again 8 hours later is sufficient to exclude BCI (50). Regarding the TnI cut-off for BCI, several studies converge on 40 ng/L. Becker et al. found that at this threshold TnI provides the best balance between sensitivity and specificity (4, 33).

However, some studies have shown that the recently implemented high-sensitivity TnT provides results comparable to TnI and is less prone to error than conventional TnT (24, 37).

In combination with ECG, measurement of troponin I is sufficient to rule out clinically significant BCI. A normal ECG together with a negative TnI result has a negative predictive value of 100%, and such patients are not at risk of cardiac instability (6, 44). Moreover, cardiac enzyme levels, particularly troponin, are more accurate than ECG findings for confirming cardiac injury (24).

**Echocardiography** (ECHO) is considered when screening tests are abnormal or when the patient's clinical status deteriorates despite thorough resuscitative therapy. Marcolini and Keegan reported that valvular injuries may be associated with normal ECG findings and cardiac enzyme levels but

are accompanied by significant clinical manifestations (29). ECHO provides both functional and structural assessment of the heart, allowing localization of wall motion abnormalities, detection of valvular damage or cardiac tamponade (29). Wiener et al. also take the ISS into account when indicating ECHO, particularly in patients with ISF (52). Sztulman et al. developed a protocol for transthoracic ECHO in polytrauma patients with an ISS of 16 or higher. This protocol was immediately implemented at a level 1 trauma center and in this study, they reported frequent findings of mitral regurgitation (50% of patients) and tricuspid regurgitation (30%) within 24 hours of injury (46). Nevertheless, current recommendations do not support the use of ECHO as a screening test and instead reserve it for symptomatic patients (6), such as those with new persistent arrhythmia, hemodynamic instability or syncope (1). Transthoracic ECHO may be difficult to perform in patients with chest wall injury, wound dressings or pneumothorax (13).

In hemodynamically unstable patients, **FAST** (Focused Assessment with Sonography in Trauma) is an important tool. It is rapid, non-invasive, and provides an overview of the patient's condition. In addition to the abdominal cavity, it assesses the pericardium and in its extended form (eFAST) the pleural space. Point-of-care echocardiography as part of POCUS (point-of-care ultrasound) also provides a rapid assessment of post-trauma cardiac status, however, including ejection fraction, chamber size, wall motion abnormalities and dilatation or collapse of the inferior vena cava. A key advantage of POCUS echocardiography is that it can be performed by emergency physicians or intensivists (54).

**CT** often serves as the diagnostic "gateway" to trauma centers. Besides the "indicator injuries" (14), patients with high-grade BCI often show traumatic changes in the mediastinum that are already visible on CT, ranging from mediastinal hematoma and pericardial effusion to pericardial "stranding", characterized by increased attenuation of pericardial fat, and injury to adjacent organs. These findings may be regarded as indirect signs of BCI (13). The sensitivity of CT for direct signs of BCI is very low, only exceptionally are hypodense myocardial areas observed, and are more often seen in the left than in the right ventricular injury due to anatomical considerations (13). In cases of uncertainty, CT angiography may be performed, especially if traumatic acute coronary syndrome (TACS) is suspected (for example coronary artery dissection) (11) or when acute myocardial infarction (AMI) is suspected. Distinguishing BCI from AMI is important as it determines subsequent approach, such as coronary catheterization or anticoagulation, which may be beneficial in AMI, but is potentially harmful for patients with BCI, especially in the presence of concomitant trauma (6).

**ECG-gated CT** or **cardiac MRI** are reserved imaging modalities for clinically unclear findings with an unexplained cause of arrhythmia or for further evaluation after the acute

post-trauma phase. These modalities allow assessment of contrast enhancement synchronized with myocardial wall motion. In the acute phase, myocardial contusion may mimic a pattern like AMI, demonstration of patent coronary arteries is therefore crucial. In the case of TACS, by contrast, the pathology is in the coronary arteries. Another limitation of these methods is their availability, MRI requires a hemodynamically stable patient and is time-consuming (6, 13).

In 2012, the **EAST** updated its 1998 recommendations on the screening for and exclusion of BCI. The final recommendations are available below, organized according to evidence-based medicine principles (6).

Level 1 recommendations are based on prospective randomized controlled trials or on strong retrospective or prospective analyses using reliable data, especially when the clinical question does not lend itself to randomized testing:

- An admission electrocardiogram (ECG) should be performed on all patients in whom BCI is suspected.

Level 2 recommendations are based on retrospective or prospective analyses, observational and cohort studies and are strongly supported by expert opinion:

- If the admission ECG reveals a new abnormality (arrhythmia, ST changes, ischemia, heart block), the patient should be admitted for continuous ECG monitoring. For patients with preexisting abnormalities, comparison should be made to a previous ECG to determine need for monitoring.
- In patients with a normal ECG result and normal troponin I level, BCI is ruled out. The optimal timing of these measurements, however, has yet to be determined. Conversely, patients with normal ECG results but elevated troponin I level should be admitted to a monitored setting.
- For patients with hemodynamic instability or persistent new arrhythmia, an echocardiogram should be obtained. If an optimal transthoracic echocardiogram cannot be performed, the patient should have a transoesophageal echocardiogram.
- The presence of a sternal fracture alone does not predict the presence of BCI and thus should not prompt monitoring in the setting of normal ECG result and troponin I level.
- Creatinine phosphokinase with isoenzyme analysis should not be performed because it is not useful in predicting which patients have or will have complications related to BCI.
- Nuclear medicine studies add little when compared with echocardiography and should not be routinely performed.

Level 3 recommendations are based on analyses of databases, registries, and case reports:

- Elderly patients with known cardiac disease, unstable patients, and those with an abnormal admission ECG result can safely undergo surgery provided, that they are

appropriately monitored. Consideration should be given to placement of a pulmonary artery catheter in such cases.

- Troponin I should be measured routinely for patients with suspected BCI; if elevated, patients should be admitted to a monitored setting and troponin I should be followed up serially, although the optimal timing is unknown.
- Cardiac computed tomography (CT) or magnetic resonance imaging (MRI) can be used to help differentiate acute myocardial infarction (AMI) from BCI in trauma patients with abnormal ECG result, cardiac enzymes, and/or abnormal echo to determine need for cardiac catheterization and/or anticoagulation.

Most trauma centers use protocols that include ECG, laboratory testing, followed by serial ECGs and TnI measurements for monitoring. The management of these patients should be undertaken in collaboration with a cardiologist (14).

## THErapy AND MANAGEMENT

This section can be divided into two parts: management of patients with BCI and management of patients with SF. These groups overlap at certain points.

Patients with blunt chest injury should undergo thorough diagnostic evaluation, including ECG, cardiac enzymes, CT examination, etc. The diagnostic findings and the patient's overall clinical status should guide management. In patients in whom **blunt cardiac injury** is suspected on basis of clinical symptoms, elevated cardiac enzymes and ECG abnormalities, hospital admission with continuous ECG monitoring for 24-48 hours is recommended. Treatment of cardiac arrhythmias includes optimization of the internal environment, oxygen therapy, administration of antiarrhythmic drugs or defibrillation for shockable rhythms (29). The most common arrhythmia in trauma patients is sinus tachycardia, in which it is essential to exclude another possible cause besides BCI and to treat it, if necessary - with fluid resuscitation, adequate analgesia or blood transfusion. Some patients may develop ST segment changes. According to Marcolini, Keegan and Plautz et al., in patients with ST-segment elevation on ECG and anginal chest pain who are candidates for coronary angiography, administration of nitroglycerin may be considered (29, 38). Physicians must not overlook TACS, in which thrombolysis is contraindicated in the setting of trauma (11). AMI may occur as a consequence of trauma, the presence of trauma does not exclude this diagnosis.

According to Gao et al., it is possible to include steps in the therapy management to protect the myocardium from overload, such as restriction of fluids and salt, administration of corticosteroids, infusion of hypertonic glucose solution, and diuretics (11), which is controversial in the management of

patients with severe polytrauma in whom a decrease in circulating volume is undesirable.

High-energy chest trauma may result in injuries that require emergent thoracotomy (myocardial or valvular rupture) (8), or pericardiocentesis, which, however, does not represent definitive treatment of the injury and the surgeon should ultimately proceed to operation (11). Surgical treatment is also required for patients with cardiac herniation or dislocation even without direct myocardial or intracardiac injury. The usual approach is an anterolateral thoracotomy, as injuries are typically located on the anterior surface of the heart, and this incision allows a thorough inspection of the entire hemithorax (11).

Management of patients with **sternal fractures** depends on associated injuries. In cases of ISF, treatment is conservative – analgesia, respiratory rehabilitation, and rest. Several studies have shown that patients with ISF do not need to be admitted to a monitored bed for 24 hours (1, 24). According to a single-center study, there was no clinically significant manifestation of any cardiac damage in a group of such patients, and BCI was not confirmed (7). In accordance with these results, the 2012 EAST guidelines recommend screening for BCI using ECG and troponin I in all patients with ISF. If at least one of these indicators is abnormal, hospitalization and monitoring are indicated. If both tests are negative, BCI is considered excluded (6). In the controversy surrounding this recommendation, hospitalization of patients with ISF for observation is still considered the standard of care (24). According to Karangelis et al., this standard is related to the fact that patients with ISF have not been evaluated separately. They created a simple algorithm to help physicians decide whether the patient requires hospitalization or not. A patient with ISF without other injuries can be safely discharged after 6-12 hours of observation on oral analgesic therapy if he meets the following criteria: normal ECG, ECHO and chest X-ray, normal cardiac enzymes, no significant history and the patient is in stable condition (22).

No specific protocol has been established for the conservative management. The base is pain relief, rest, respiratory rehabilitation, and with an optional administration of nebulization or other expectorants (24). All these measures are essential for preventing respiratory complications. In this context, hospitalization of patients with SF is not necessarily indicated based solely on suspected BCI. Risk groups (elderly or immunocompromised patients) may benefit from hospitalization where adequate therapy can be provided. These patients are at increased risk of atelectasis and pulmonary complications (7). With the higher prevalence of comorbidities and more frequent positive cardiac history in elderly patients, some authors also recommend short-term hospitalization (22, 50).

Indications for surgical stabilization of SF in the acute phase include significant displacement of the fragments or

fracture instability (7, 43). Fixation options include transfixation with wires or osteosynthesis using screws or a plate (24).

Patient follow-up is performed to monitor the pain management and the healing process. No specific diagnostic or interventional treatment is necessary in patients with SF during follow-up unless the patient's symptoms require it (7).

Patients with combined SF are hospitalized and monitored regarding the mechanism of injury and associated injuries. Treatment is focused on the concomitant extra- and intrathoracic injuries and would be provided even if SF were not present (37).

## DISCUSSION AND CONCLUSION

The relationship between SF and BCI remains somewhat controversial. This is largely due to the nature of BCI itself, which lacks precise definitions and diagnostic criteria. Compounding the problem, some authors do not distinguish between BCI and cardiac contusion. There are large differences in the available studies, most often because they employ different methodologies. EAST attempted to establish at least a general approach in 2012, however, this recommendation ultimately underlines the ambiguities in this topic.

BCI may be clinically silent at first and manifest only with deterioration of the patient's condition (for example during surgery) or it may be clinically significant from the beginning. Clinically significant BCI can present with cardiogenic shock, arrhythmias requiring treatment, structural posttraumatic cardiac defects, or unexplained hypotension requiring further therapy. Key questions are, when clinically significant BCI occurs, whether it is associated with SF, and how it can be detected at an early stage (1, 50).

Authors do not fully agree on the definition of isolated SF. Several studies show that the risk of clinically significant BCI is minimal in patients with CT-confirmed ISF, if ECG is normal, cardiac enzymes are not elevated, no abnormal clinical findings are present in a hemodynamically stable patient, and the history shows no major comorbidities with emphasis on a negative cardiac history. Al-Khouja et al. used AIS to define ISF as SF without other significant injuries, that is, with AIS < 2 for the head and neck, face, abdomen, and extremities (1). Wiener et al. defined ISF as the presence of ISF in a patient with ISS of 5 or less (52). The issue of polytrauma patients with SF remains unresolved. The further problem is the terminology and the definition of the "second group" of patients, those without ISF. Some studies compare the ISF group with a group of polytrauma who also have SF (28), whereas others compare them with patients who have only associated injuries of ribs, thoracic spine, pneumothorax or other thoracic injuries, who do not necessarily meet the criteria for polytrauma. Polytrauma is defined as trauma involving two or more systems, with at least one injury directly

threatening the patient's life. The stricter and more recent Berlin definition, established by an international consensus of trauma societies and published in 2014, characterizes polytrauma as severe injury (AIS  $\geq$  3) in two or more body compartments in combination with the presence of at least one of the following five criteria: hypotension, unconsciousness, acidosis, coagulopathy or age  $\geq$  70 years (36). So far, this definition has not been applied in published studies other than the cited work.

According to the Centers for Disease Control and Prevention in the United States, trauma is the leading cause of death in individuals under 44 years of age, and 25% of these deaths are due to BCI (53). Hanschen et al. reported that, among surviving patients transported to hospital, BCI was associated

with early mortality in 7.2% and an overall mortality rate of 13.9% (14). Ishida et al. reported an in-hospital mortality rate of up to 23% for BCI (43). Deaths in patients with SF are usually not directly related to the fracture itself, but rather to associated injuries such as vertebral fractures, pulmonary contusions/lacerations, hemopneumothorax, mediastinal injury, and, in fact, BCI itself (43).

In conclusion, **BCI should be considered in patients after high-energy trauma with multiple associated injuries. ECG and measurement of cardiac enzyme represent the basic screening methods.** The implementation of standardized diagnostic protocols – ECG and cardiac enzyme monitoring – would facilitate early identification patients with BCI and timely initiation of appropriate treatment. ■

## References

- Al-Khouja F, Grigorian A, Emigh B, Schellenberg M, Diaz G, Duncan TK, Tuli R, Coimbra R, Gilbert-Gard K, Johnson A, Marty M, Jebbia M, Obaid-Schmid AK, Fierro N, Ley E, Bayat D, Biffi W, Ebrahimian S, Tillou M A, Tay-Lasso E, Alvarez C, Nahmias J. 24-hour Telemetry Monitoring May Not be Necessary for Patients With an Isolated Sternal Fracture and Minor ECG Abnormalities or Troponin Elevation: A Southern California Multicenter Study. *Am Surg.* 2025;91:126-132.
- American Association for the Surgery of Trauma. Blunt cardiac injury [online]. Chicago (IL): American Association for the Surgery of Trauma; [cited 2025 Jun 18]. Available from: <https://www.aast.org/resources-detail/blunt-cardiac-injury>
- Andrews RP, McAfee RE. Sternal fractures secondary to seat belt injury: price for survival. *J Maine Med Assoc.* 1967;58:187-190.
- Becker ER, Price AD, Whitrock JN, Smith M, Baucom MR, Makley AT, Goodman MD. Re-evaluating the Use of High Sensitivity Troponin to Diagnose Blunt Cardiac Injury. *J Surg Res.* 2024;300:150-156.
- Burchell HB. Unusual forms of heart disease. *Circulation.* 1954;10:574-579.
- Clancy K, Velopulos C, Bilaniuk JW, Collier B, Crowley W, Kurek S, Lui F, Nayduch D, Sangosanya A, Tucker B, Haut ER; Eastern Association for the Surgery of Trauma. Screening for blunt cardiac injury: an Eastern Association for the Surgery of Trauma practice management guideline. *J Trauma Acute Care Surg.* 2012;73(5 Suppl 4):S301-S306.
- Dua A, McMaster J, Desai PJ, Desai SS, Kuy S, Mata M, Cooper J. The Association between Blunt Cardiac Injury and Isolated Sternal Fracture. *Cardiol Res Pract.* 2014;2014:629687.
- El-Menyar A, Al Thani H, Zarour A, Latifi R. Understanding traumatic blunt cardiac injury. *Ann Card Anaesth.* 2012;15:287-295.
- Fokin AA, Wycech Knight J, Abid AT, Yoshinaga K, Alayon AL, Grady R, Weisz RD, Puente I. Sternal fractures in blunt trauma patients. *Eur J Trauma Emerg Surg.* 2022;48:2987-2998.
- Galvagno SM Jr, Nahmias JT, Young DA. Advanced Trauma Life Support® Update 2019: Management and Applications for Adults and Special Populations. *Anesthesiol Clin.* 2019;37:13-32.
- Gao JM, Du DY, Kong LW, Yang J, Li H, Wei GB, Li CH, Liu CP. Emergency Surgery for Blunt Cardiac Injury: Experience in 43 Cases. *World J Surg.* 2020;44:1666-1672.
- Grigorian A, Milliken J, Livingston JK, Spencer D, Gabriel V, Schubl SD, Kong A, Barrios C, Joe V, Nahmias J. National risk factors for blunt cardiac injury: Hemopneumothorax is the strongest predictor. *Am J Surg.* 2019;217:639-642.
- Hammer MM, Raptis DA, Cummings KW, Mellnick VM, Bhalla S, Schuerer DJ, Raptis CA. Imaging in blunt cardiac injury: Computed tomographic findings in cardiac contusion and associated injuries. *Injury.* 2016;47:1025-1030.
- Hanschen M, Kanz KG, Kirchoff C, Khalil PN, Wierer M, van Griensven M, Laugwitz KL, Biberthaler P, Lefering R, Huber-Wagner S; TraumaRegister DGU. Blunt Cardiac Injury in the Severely Injured - A Retrospective Multicentre Study. *PLoS One.* 2015;10:e0131362.
- Heidelberg L, Uhlich R, Bosarge P, Kerby J, Hu P. The Depth of Sternal Fracture Displacement Is Not Associated With Blunt Cardiac Injury. *J Surg Res.* 2019;235:322-328.
- Huber S, Biberthaler P, Delhey P, Trentzsch H, Winter H, van Griensven M, Lefering R, Huber-Wagner S; Trauma Register DGU. Predictors of poor outcomes after significant chest trauma in multiply injured patients: a retrospective analysis from the German Trauma Registry (Trauma Register DGU®). *Scand J Trauma Resusc Emerg Med.* 2014;22:52.
- Huis In 't Veld MA, Craft CA, Hood RE. Blunt Cardiac Trauma Review. *Cardiol Clin.* 2018;36:183-191.
- Ishida K, Katayama Y, Kitamura T, Hirose T, Ojima M, Nakao S, Tachino J, Umemura Y, Kiguchi T, Matsuyama T, Noda T, Kiyohara K, Oda J, Ohnishi M. Factors Associated with Cardiac/

- Pericardial Injury among Blunt Injury Patients: A Nationwide Study in Japan. *J Clin Med*. 2022;11:4534.
19. Jiang Y, Zhou G, Feng J, Ma L, Pan J. Injury mechanism, risk factors and outcomes associated with blunt cardiac injury: a systematic review and meta-analysis. *Cardiol Plus*. 2023;8:53-62.
  20. Johnson I, Branfoot T. Sternal fracture—a modern review. *Arch Emerg Med*. 1993;10:24-28.
  21. Kara H, Bayir A, Degirmenci S, Yildiran H, Kafali ME, Ak A. Sternal Fractures in Blunt Chest Trauma: Retrospective Analysis of 330 Cases. *J Coll Physicians Surg Pak*. 2022;32:799-803.
  22. Karangelis D, Bouliaris K, Koufakis T, Spiliopoulos K, Desimonas N, Tsilimigias N. Management of isolated sternal fractures using a practical algorithm. *J Emerg Trauma Shock*. 2014;7:170-173.
  23. Kouritas VK, Zisis C, Vahlas K, Roussakis AG, Bellenis I. Isolated sternal fractures treated on an outpatient basis. *Am J Emerg Med*. 2013;31:227-230.
  24. Kunhivalappil FT, Almansoori TM, AbdulRahman MS, Hefny MA, Mansour NA, Zoubeidi T, Khan MAB, Hefny AF. Management of Blunt Sternal Fractures in a Community-Based Hospital. *Surg Res Pract*. 2023;2023:8896989.
  25. Kuru M, Sahinoglu T. Are sternum fractures really indicative of severe trauma? *Ann Med Res*. 2019;26(10):2219-2223.
  26. Kyriazidis IP, Jakob DA, Vargas JAH, Franco OH, Degiannis E, Dorn P, Pouwels S, Patel B, Johnson I, Houdlen CJ, Whiteley GS, Head M, Lala A, Mumtaz H, Soler JA, Mellor K, Rawaf D, Ahmed AR, Ahmad SJS, Exadaktylos A. Accuracy of diagnostic tests in cardiac injury after blunt chest trauma: a systematic review and meta-analysis. *World J Emerg Surg*. 2023;18:36.
  27. Ma DS, Ryu JW, Noh D. Direct cardiac rupture associated with sternal fracture following blunt trauma: A report of two case. *Trauma Case Rep*. 2021;32:100430.
  28. Mahmood I, El-Menyar A, Dabdoob W, Abdulrahman Y, Siddiqui T, Atique S, Arumugam SK, Latifi R, Al-Thani H. Troponin T in patients with traumatic chest injuries with and without cardiac involvement: insights from an observational study. *N Am J Med Sci*. 2016;8:17-24.
  29. Marcolini EG, Keegan J. Blunt Cardiac Injury. *Emerg Med Clin North Am*. 2015;33:519-527.
  30. Mattox KL, Flint LM, Carrico CJ, Grover F, Meredith J, Morris J, Rice C, Richardson D, Rodriguez A, Trunkey DD. Blunt cardiac injury. *J Trauma*. 1992;33:649-650.
  31. Meinberg EG, Agel J, Roberts CS, Karam MD, Kellam JF. Fracture and Dislocation Classification Compendium-2018. *J Orthop Trauma*. 2018;32(Suppl 1):S1-S170.
  32. Nair L, Winkle B, Senanayake E. Managing blunt cardiac injury. *J Cardiothorac Surg*. 2023;18:71.
  33. Nathwani JN, Baucom MR, Salvator A, Makley AT, Tsuei BJ, Droege CA, Goodman MD, Nomellini V. Evaluating the utility of high sensitivity troponin in blunt cardiac injury. *J Surg Res*. 2023;281:104-111.
  34. Odell DD, Peleg K, Givon A, Radomislensky I, Makey I, Decamp MM, Whyte R, Gangadharan SP, Berger RL; Israeli Trauma Group. Sternal fracture: isolated lesion versus polytrauma from associated extrasternal injuries—analysis of 1,867 cases. *J Trauma Acute Care Surg*. 2013;75:448-452.
  35. Oyetunji TA, Jackson HT, Obirize AC, Moore D, Branche MJ, Greene WR, Cornwell EE 3rd, Siram SM. Associated injuries in traumatic sternal fractures: a review of the National Trauma Data Bank. *Am Surg*. 2013;79:702-705.
  36. Pape HC, Lefering R, Butcher N, Peitzman A, Leenen L, Marzi I, Lichte P, Josten C, Bouillon B, Schmucker U, Stahel P, Giannoudis P, Balogh Z. The definition of polytrauma revisited: An international consensus process and proposal of the new 'Berlin definition'. *J Trauma Acute Care Surg*. 2014;77:780-786.
  37. Perez MR, Rodriguez RM, Baumann BM, Langdorf MI, Anglin D, Bradley RN, Medak AJ, Mower WR, Hendey GW, Nishijima DK, Raja AS. Sternal fracture in the age of pan-scan. *Injury*. 2015;46:1324-1327.
  38. Plautz CU, Perron AD, Brady WJ. Electrocardiographic ST-segment elevation in the trauma patient: acute myocardial infarction vs myocardial contusion. *Am J Emerg Med*. 2005;23:510-516.
  39. Porter RS, Zhao N. Patterns of injury in belted and unbelted individuals presenting to a trauma center after motor vehicle crash: seat belt syndrome revisited. *Ann Emerg Med*. 1998;32:418-424.
  40. Sağlam Gürmen E, Tulay CM. Attention: Cardiac contusion. *Ulus Travma Acil Cerrahi Derg*. 2022;28:634-640.
  41. Scheyerer MJ, Zimmermann SM, Bouaicha S, Simmen HP, Wanner GA, Werner CM. Location of sternal fractures as a possible marker for associated injuries. *Emerg Med Int*. 2013;2013:407589.
  42. Shoar S, Hosseini FS, Naderan M, Khavandi S, Tabibzadeh E, Khavandi S, Shoar N. Cardiac injury following blunt chest trauma: diagnosis, management, and uncertainty. *Int J Burns Trauma*. 2021;11:80-89.
  43. Şimşek S, Özmen CA, Onat S. Morbidity and mortality associated with fracture of the sternum due to blunt trauma, by fracture type and location. *Radiol Bras*. 2022;55:167-172.
  44. Skinner DL, Laing GL, Rodseth RN, Ryan L, Hardcastle TC, Muckart DJ. Blunt cardiac injury in critically ill trauma patients: a single centre experience. *Injury*. 2015;46:66-70.
  45. Son YN, Kim JI, Lee HN, Shin SY. Retrosternal hematoma in sternal fracture for prediction of concomitant injury on chest CT. *Acta Radiol*. 2021;62:1610-1617.
  46. Sztulman L, Ritter A, de Rosa R, Pfeiffer V, Leppik L, Busse LC, Kontaxi E, Störmann P, Verboket R, Adam E, Marzi I, Weber B. Cardiac damage after polytrauma: the role of systematic transthoracic echocardiography – a pilot study. *World J Emerg Surg*. 2025;20:21.
  47. Turan AA, Karayel FA, Akyildiz E, Pakis I, Uzun I, Gurpinar K, Atilmis U, Kir Z. Cardiac injuries caused by blunt trauma: an autopsy based assessment of the injury pattern. *J Forensic Sci*. 2010;55:82-84.
  48. Uz İ, Üstsoy E, Özçete E, Özdil A, Çinkoğlu A, Ersel M. Factors affecting discharge of patients with sternal fractures. *Ege J Med*. 2021;60:70-75.

49. Van Lieshout EMM, Verhofstad MHJ, Van Silfhout DJT, Dubois EA. Diagnostic approach for myocardial contusion: a retrospective evaluation of patient data and review of the literature. *Eur J Trauma Emerg Surg.* 2021;47:1259-1272.
50. Velmahos GC, Karaiskakis M, Salim A, Toutouzas KG, Murray J, Asensio J, Demetriades D. Normal electrocardiography and serum troponin I levels preclude the presence of clinically significant blunt cardiac injury. *J Trauma.* 2003;54:45-50.
51. von Garrel T, Ince A, Junge A, Schnabel M, Bahrs C. The sternal fracture: radiographic analysis of 200 fractures with special reference to concomitant injuries. *J Trauma.* 2004;57:837-844.
52. Wiener Y, Achildiev B, Karni T, Halevi A. Echocardiogram in sternal fracture. *Am J Emerg Med.* 2001;19:403-405.
53. Wilson RF, Murray C, Antonenko DR. Nonpenetrating thoracic injuries. *Surg Clin North Am.* 1977;57:17-36.
54. Yamada H, Ito H, Fujiwara M. Cardiac and vascular point-of-care ultrasound: current situation, problems, and future prospects. *J Med Ultrason (2001).* 2022;49:601-608.
55. Yeh DD, Hwabejire JO, DeMoya MA, Alam HB, King DR, Velmahos GC. Sternal fracture—an analysis of the National Trauma Data Bank. *J Surg Res.* 2014;186:39-43.
56. Yolgösteren A, Yüksel A, Kan İi, Durak VA. Is hospitalization necessary in isolated traumatic sternal fractures? *Eur Res J.* 2020;6:661-664.
57. Yousef R, Carr JA. Blunt cardiac trauma: a review of the current knowledge and management. *Ann Thorac Surg.* 2014;98:1134-1140.